

The 19th Congress of the IAP/AD
7-9/ December, 2007
Sheraton Hotel Aleppo - SYRIA

Sharif EL SALEM, M.D.

Damascus University

Al Assad University Hospital

Damascus- Syria



(Damascus)



Fac Med



Assad UH

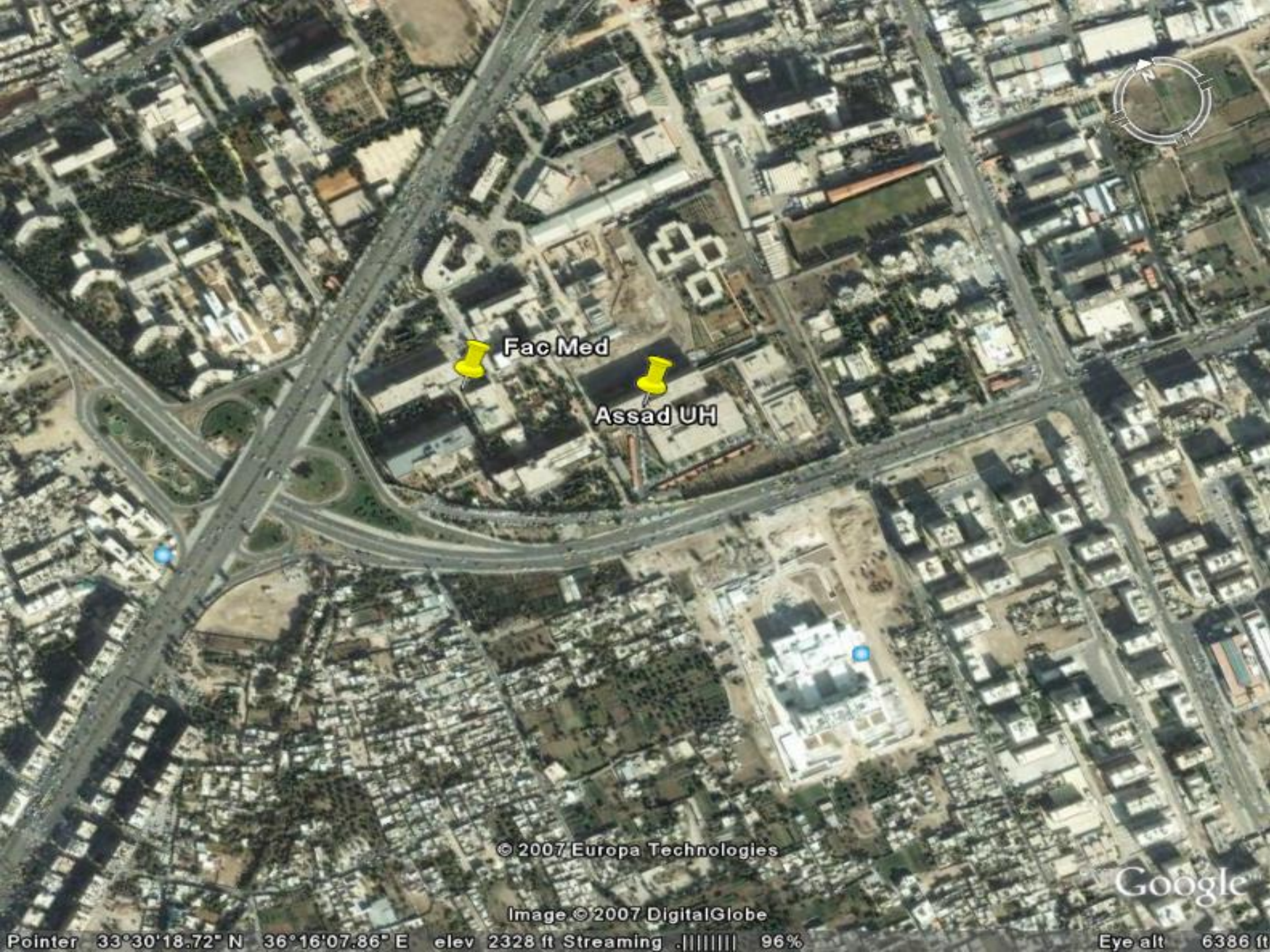Dâraiya

Ma'adamiet Shih

© 2007 Europa Technologies

Image © 2007 DigitalGlobe

Google



Fac Med

Assad UH

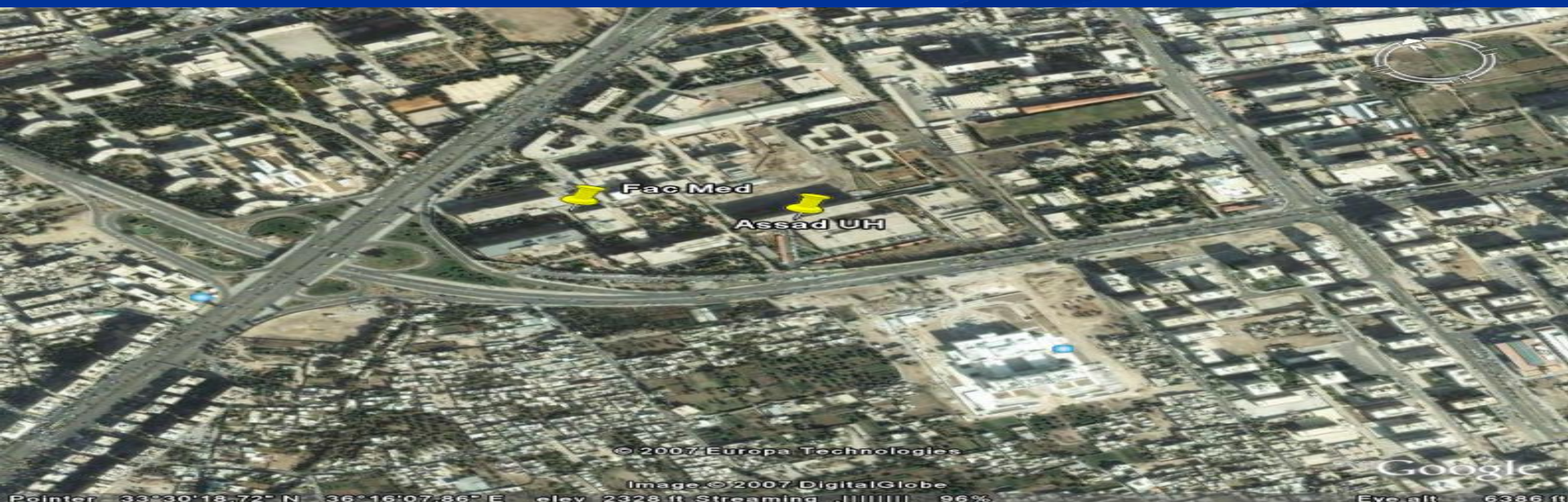© 2007 Europa Technologies

Image © 2007 DigitalGlobe

Pointer 33°30'18.72" N 36°16'07.86" E elev 2328 ft Streaming .||||||| 96%

Google

Eye alt 6386 ft



© 2007 Europa Technologies

Image © 2007 DigitalGlobe

Pointer 33°30'18.72" N 36°16'07.86" E

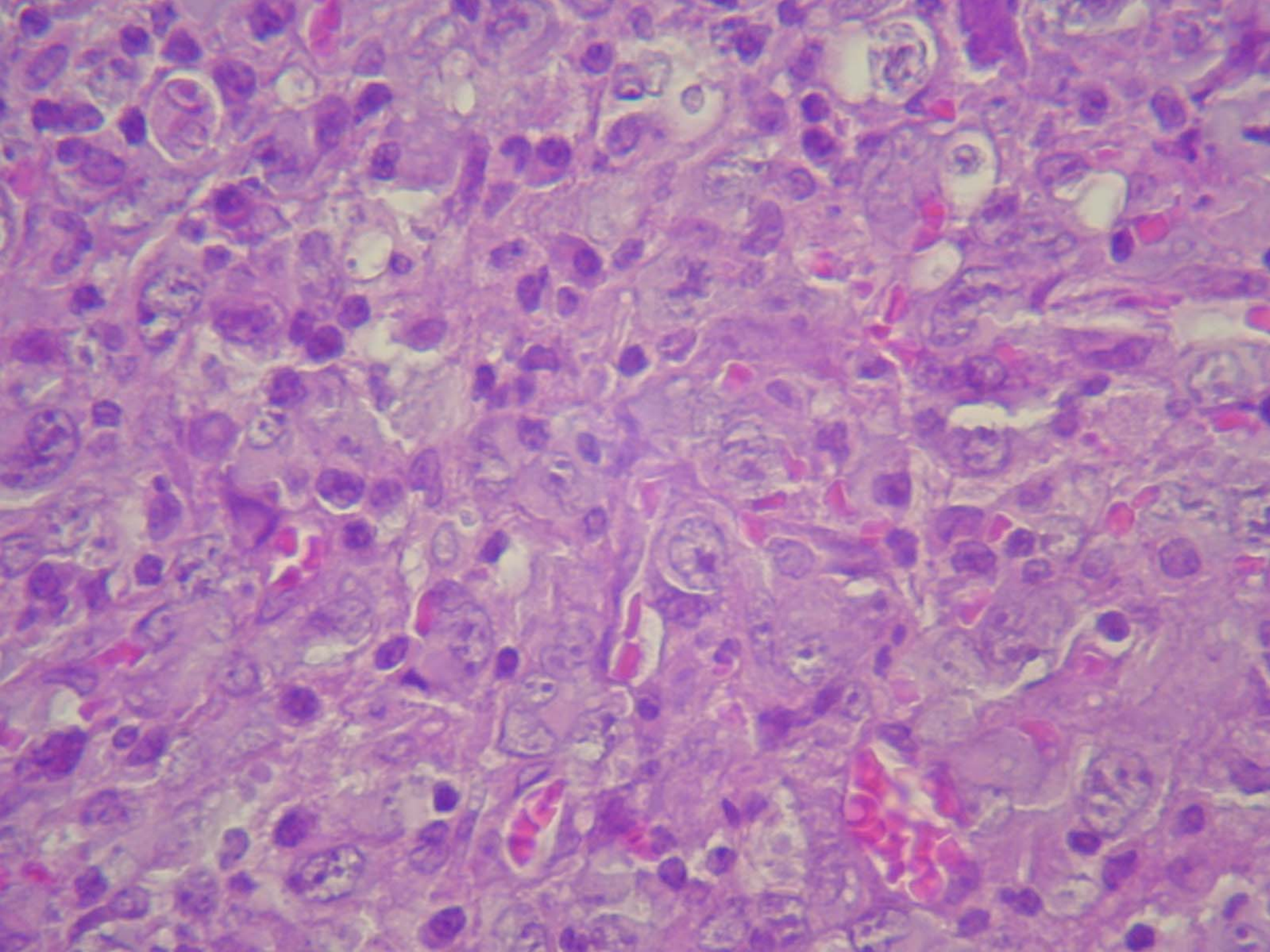
elev 2328 ft Streaming .||||||| 96%

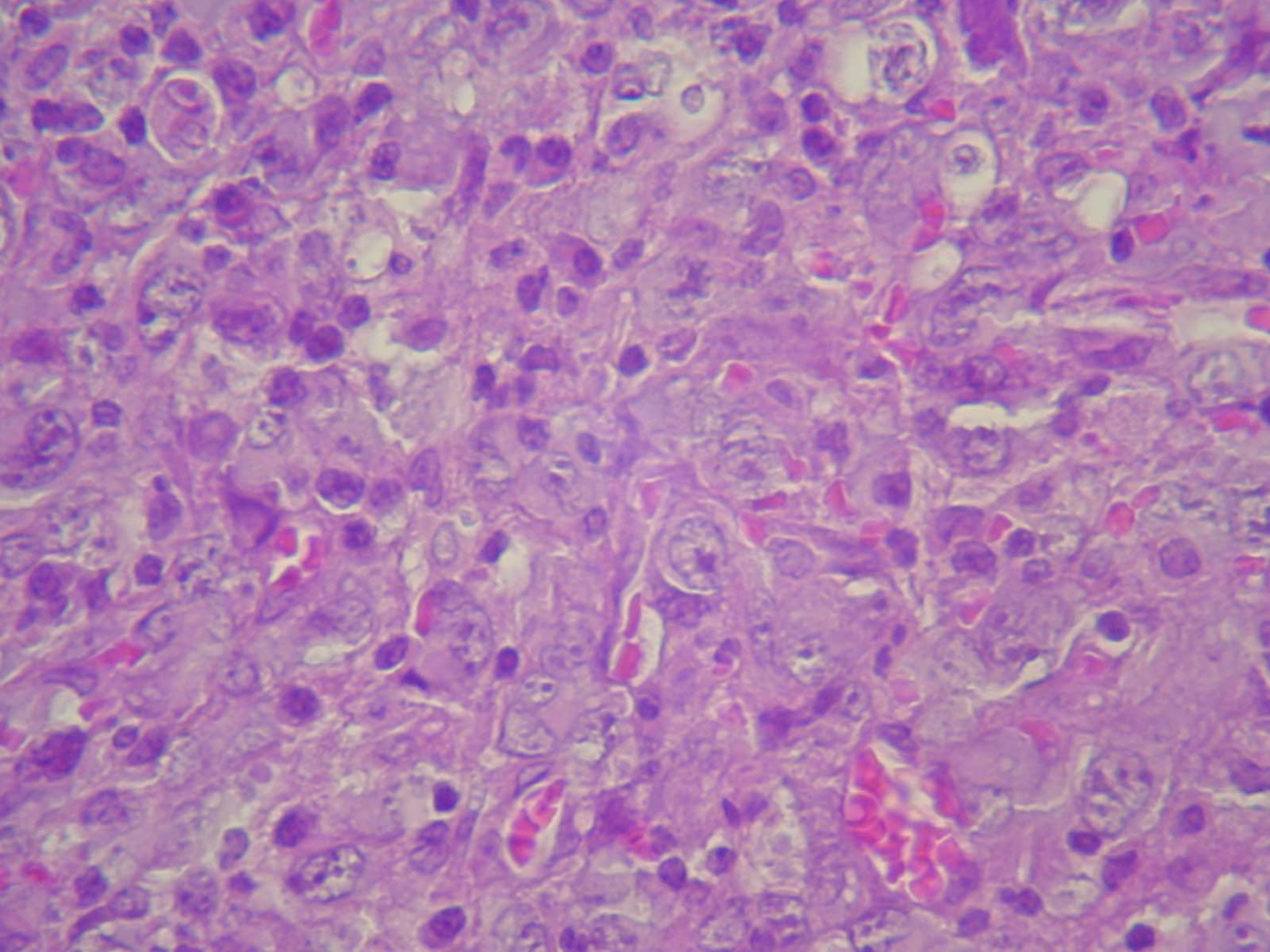
Google

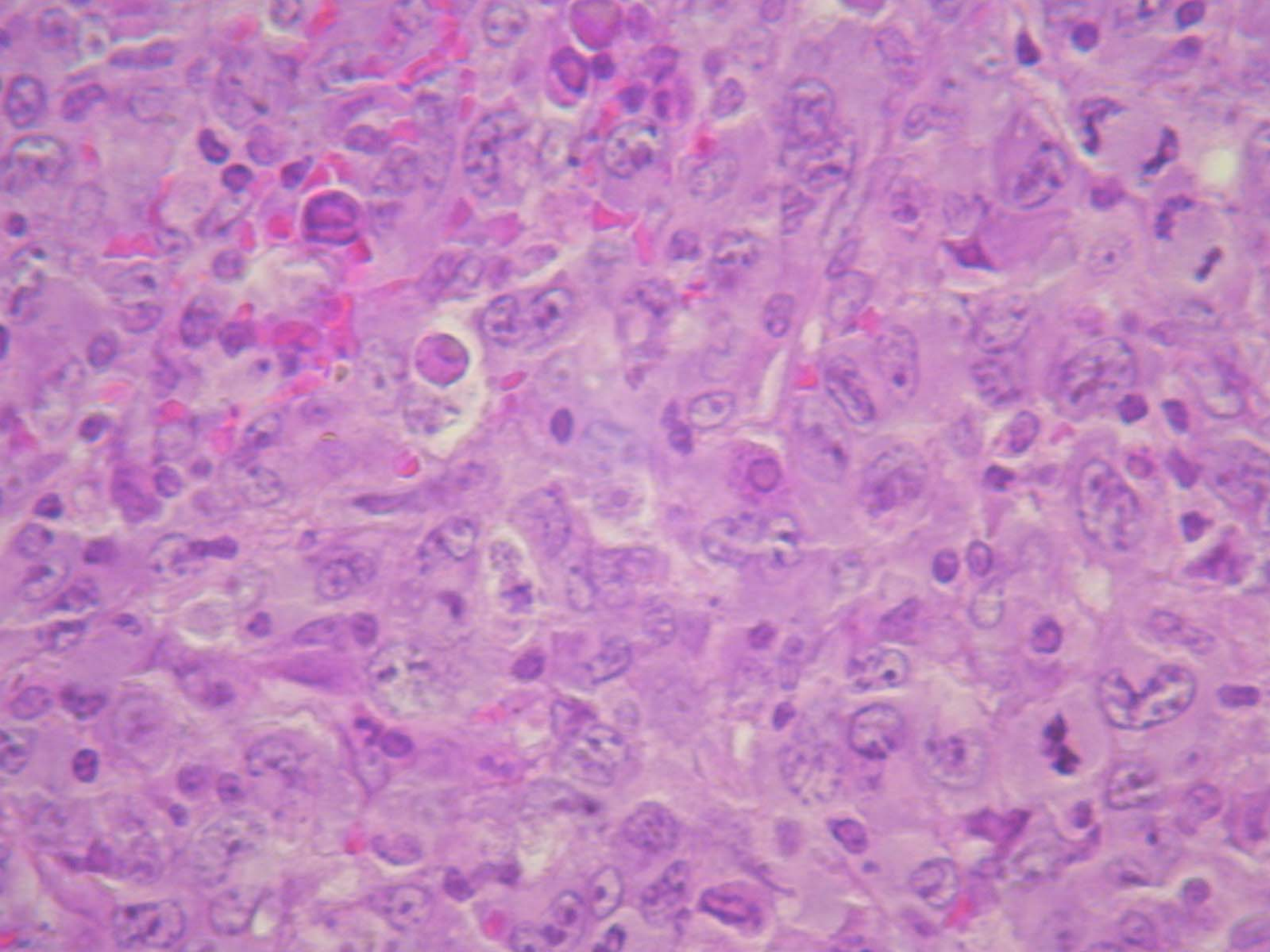
Eye alt 6386

Case 1 (07 4538)

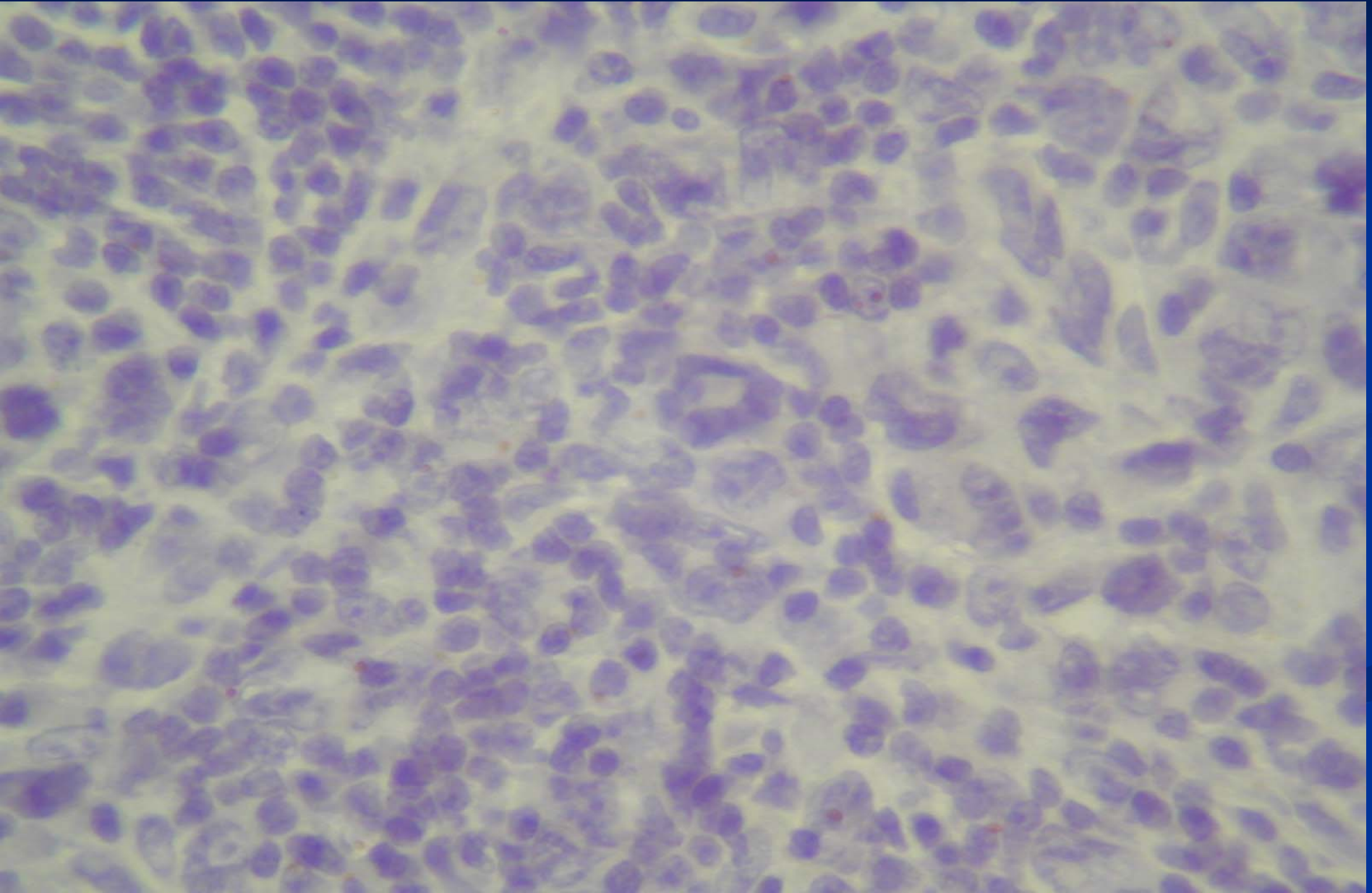
- 15 year old female
- Polyadenopathy, axillary & cervical
- Skin eruption, papules, pigmented non prurigenous in the neck, trunk and member)
- Received:
 1. Axillary lymph node
 2. Skin biopsy



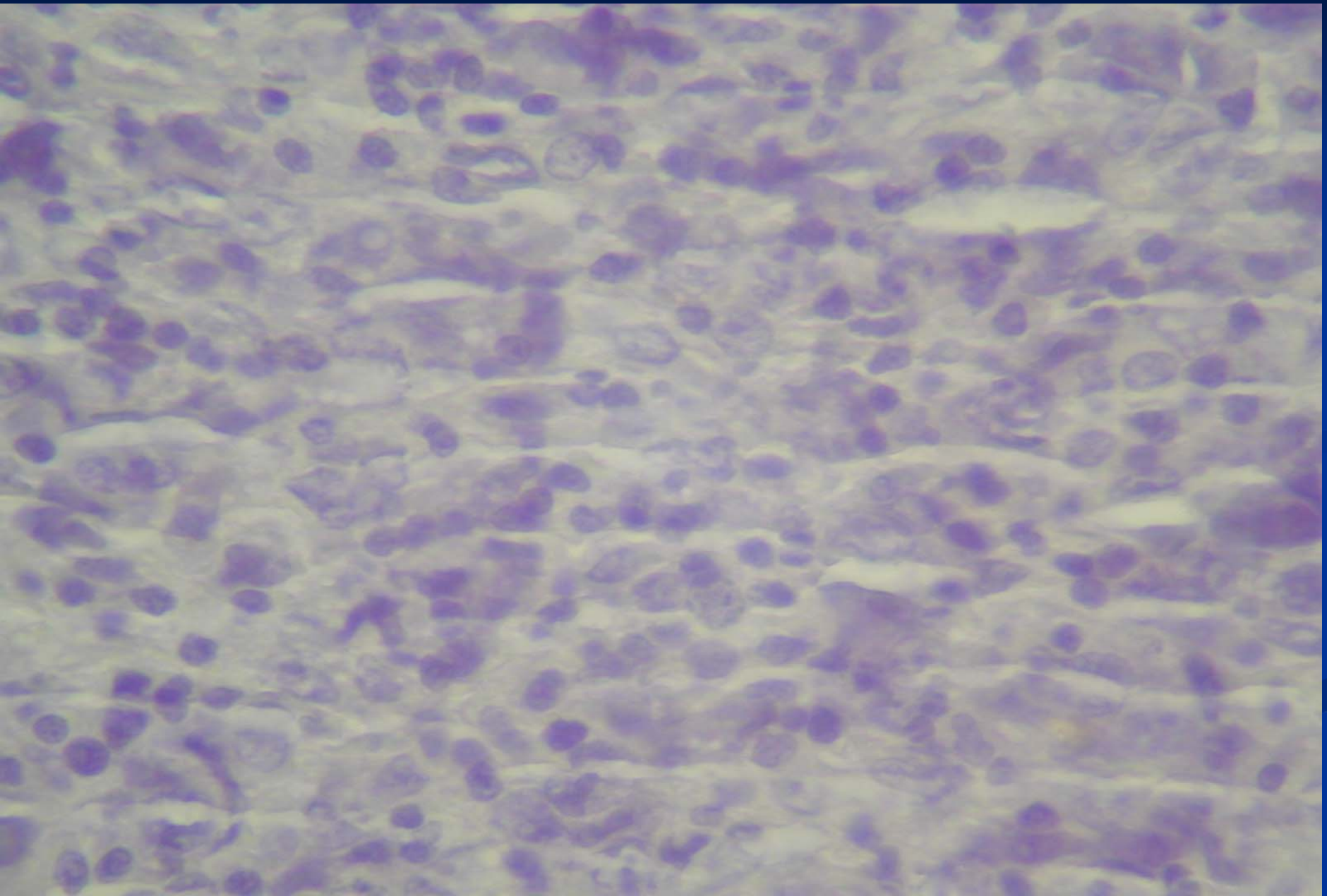




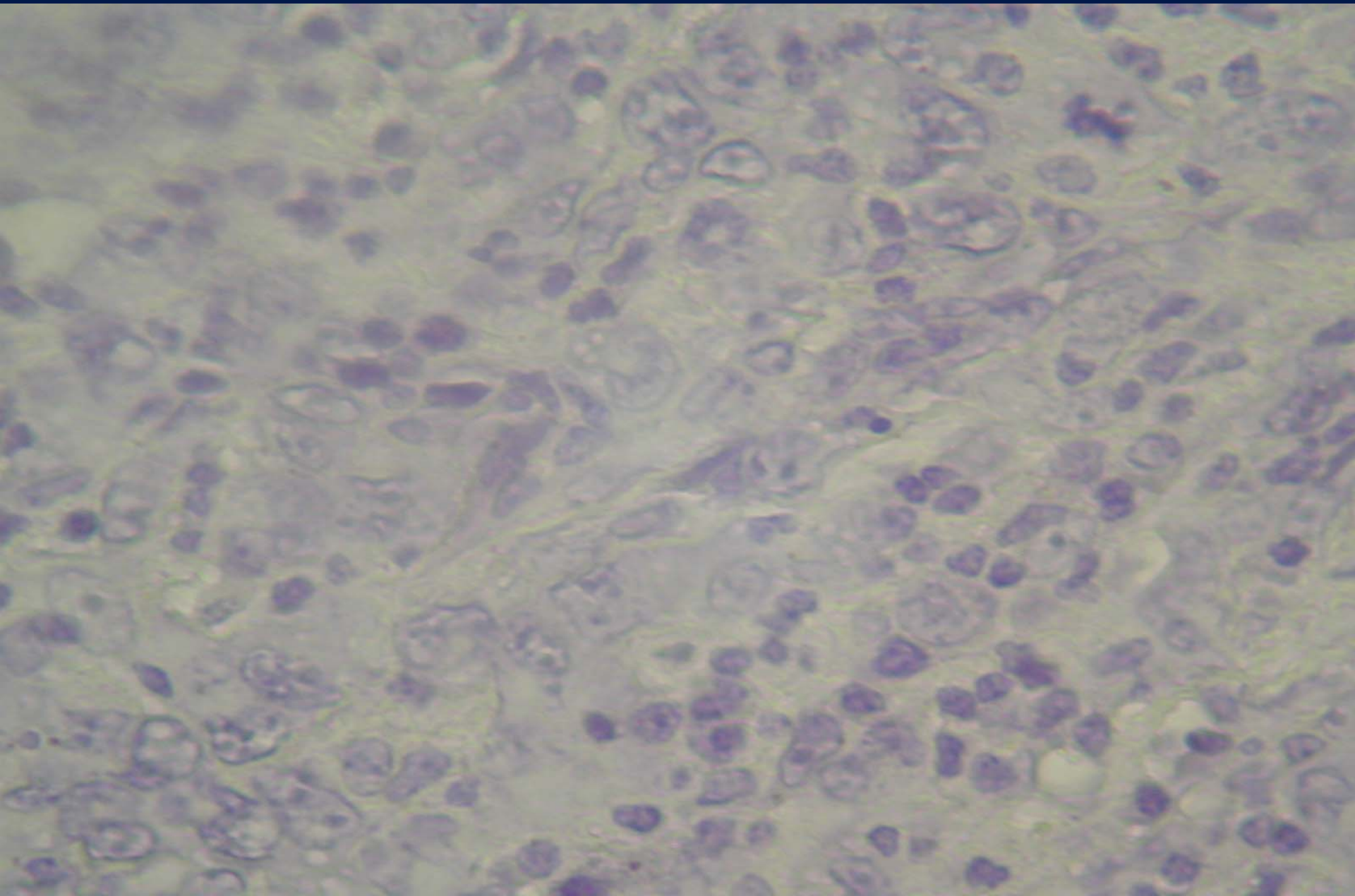
CK



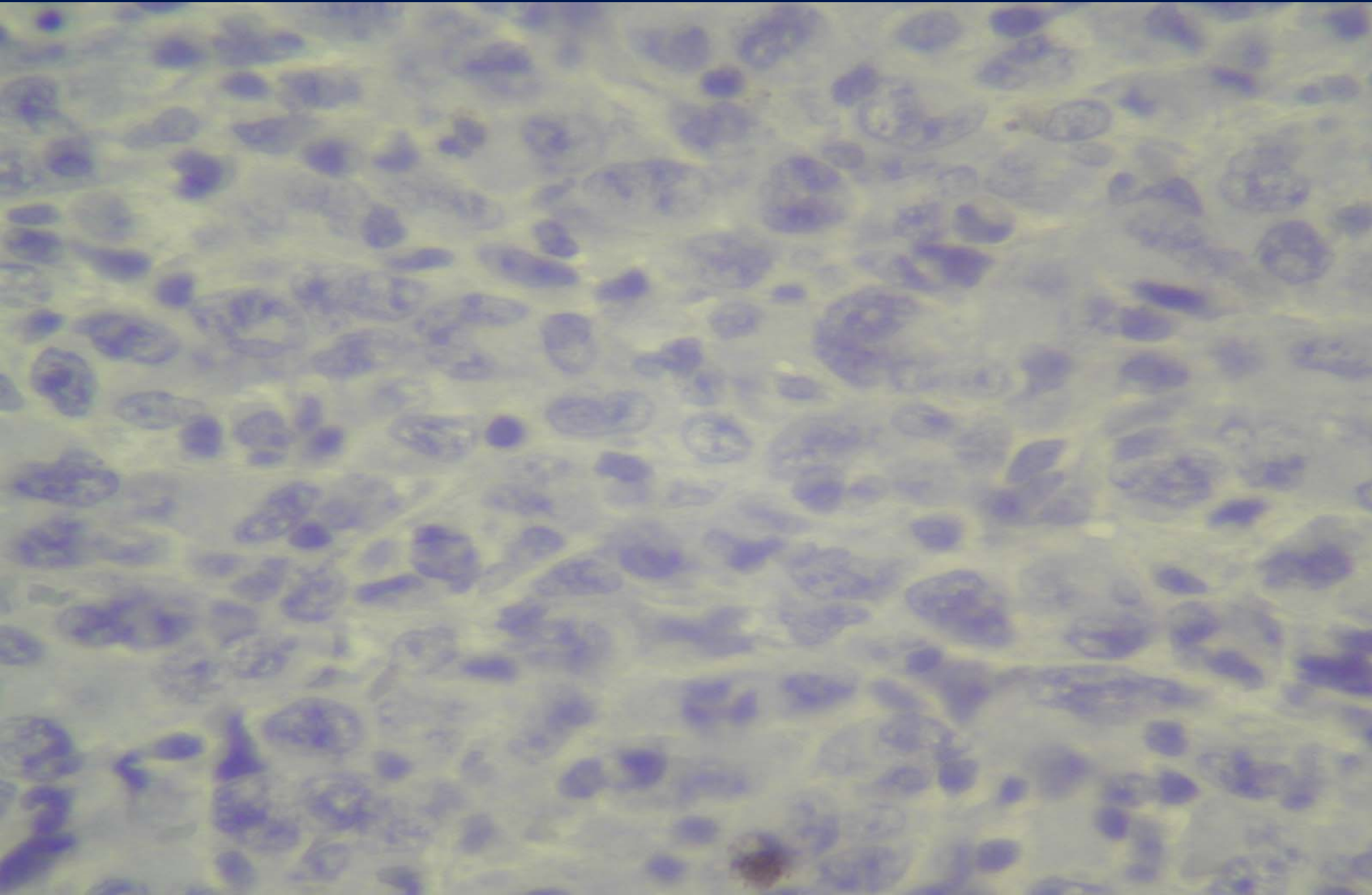
P S100



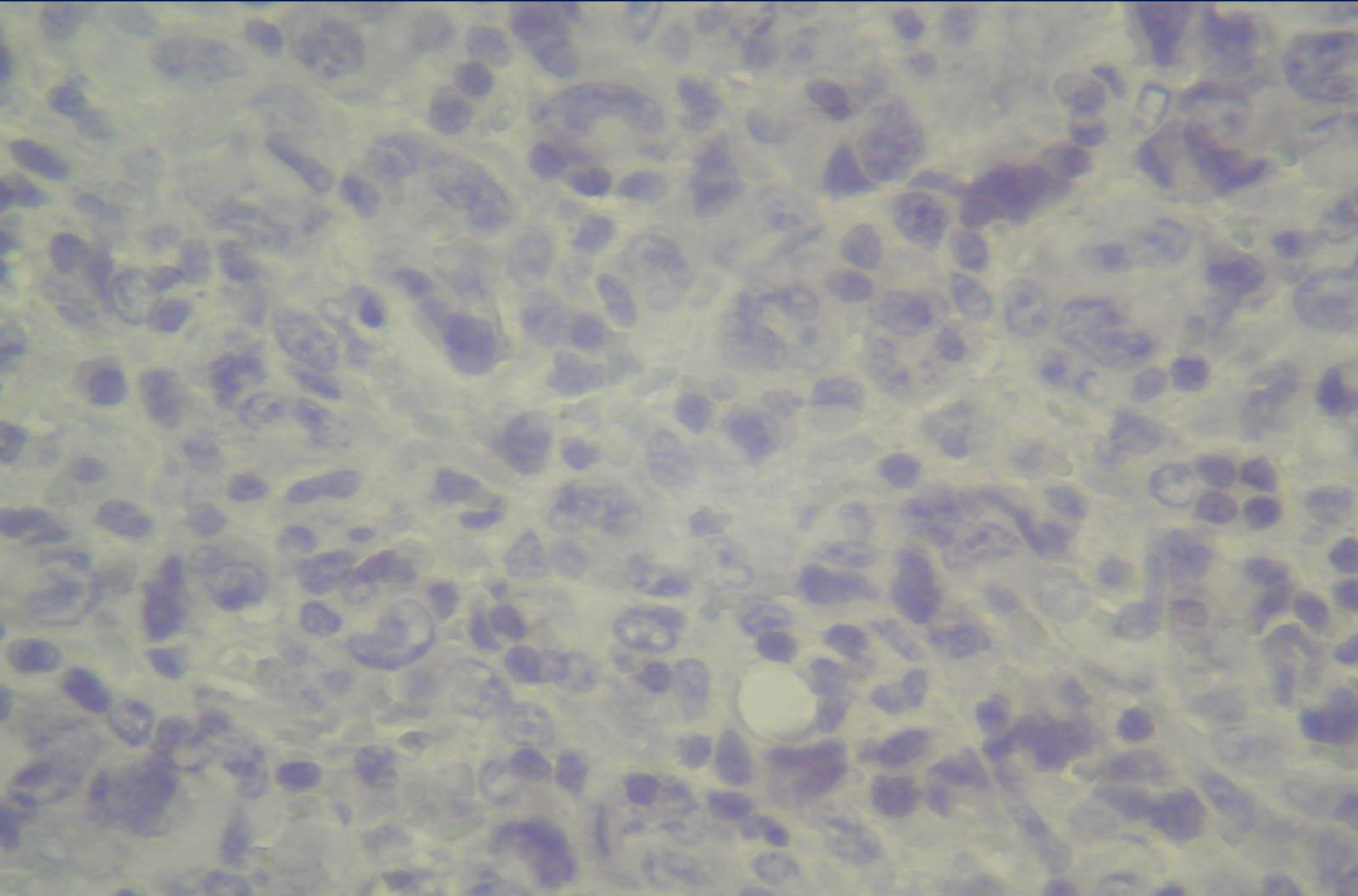
CD 20



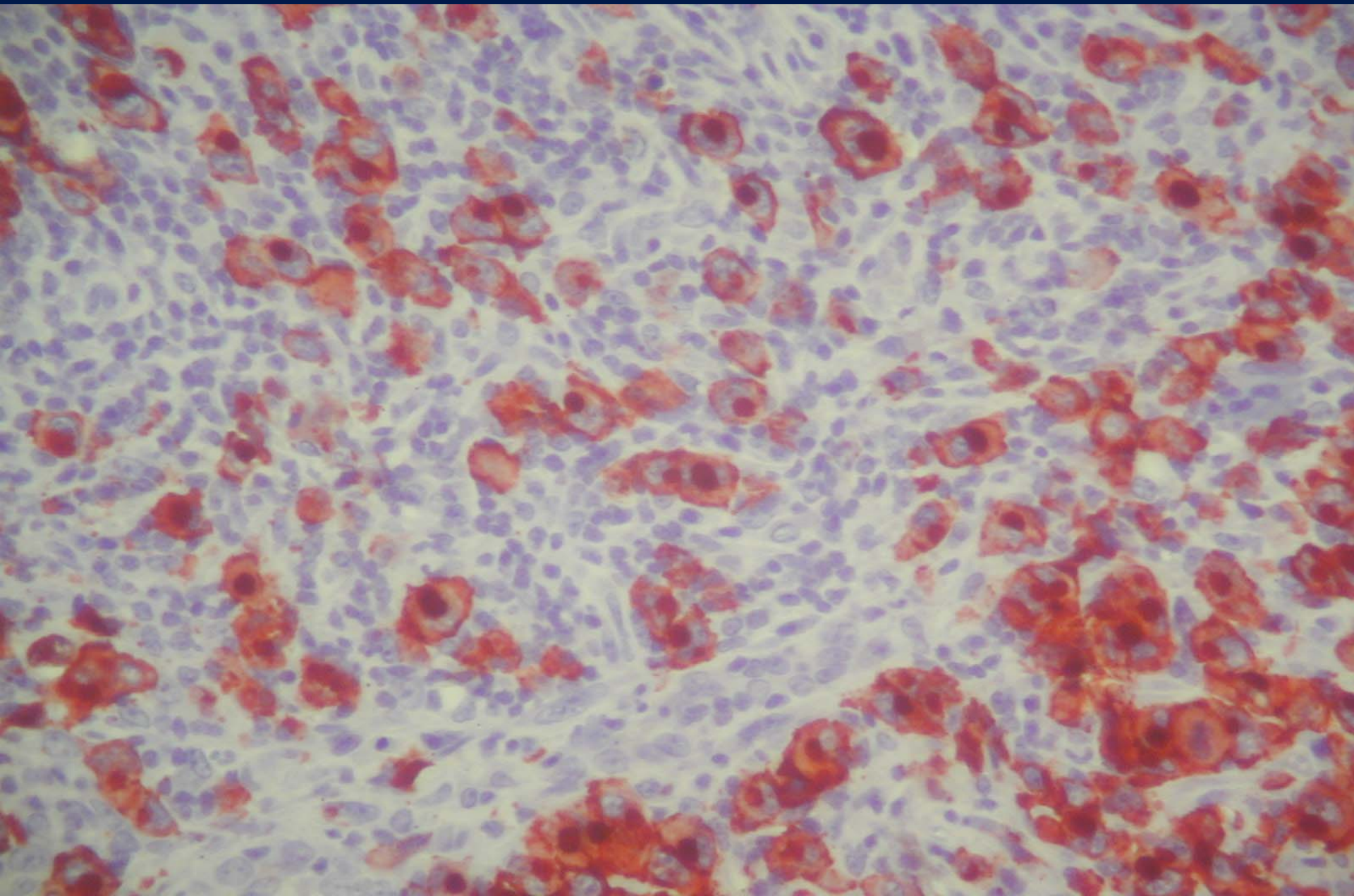
CD3



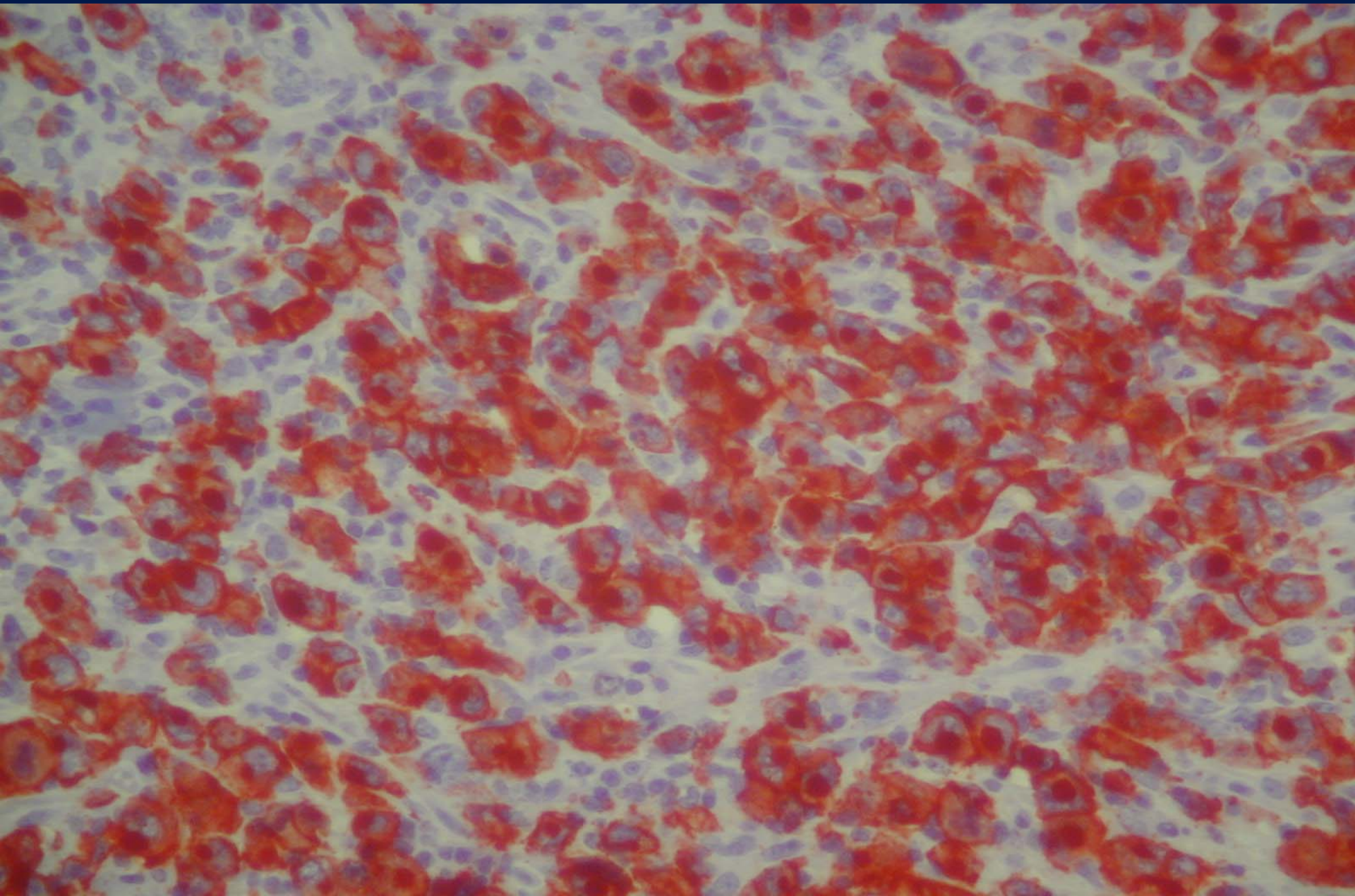
CD 15



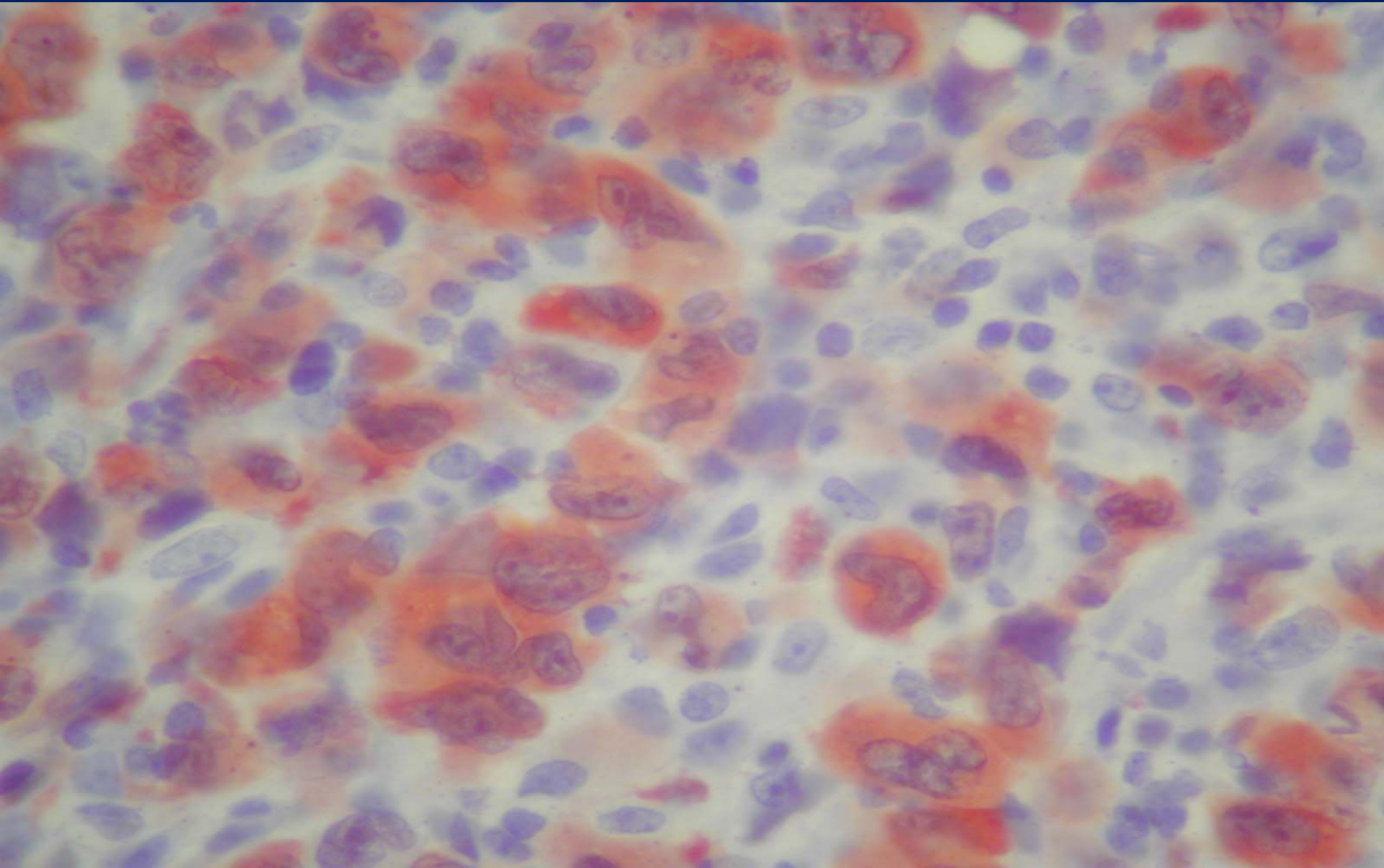
CD 30



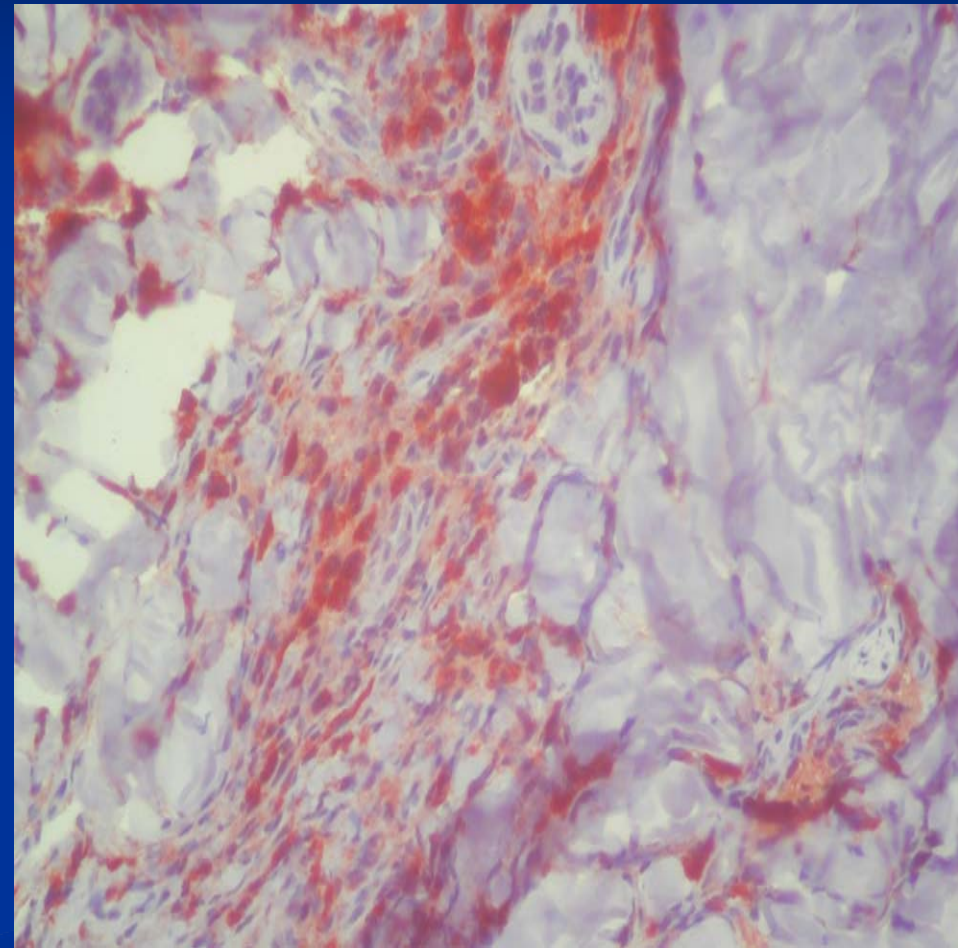
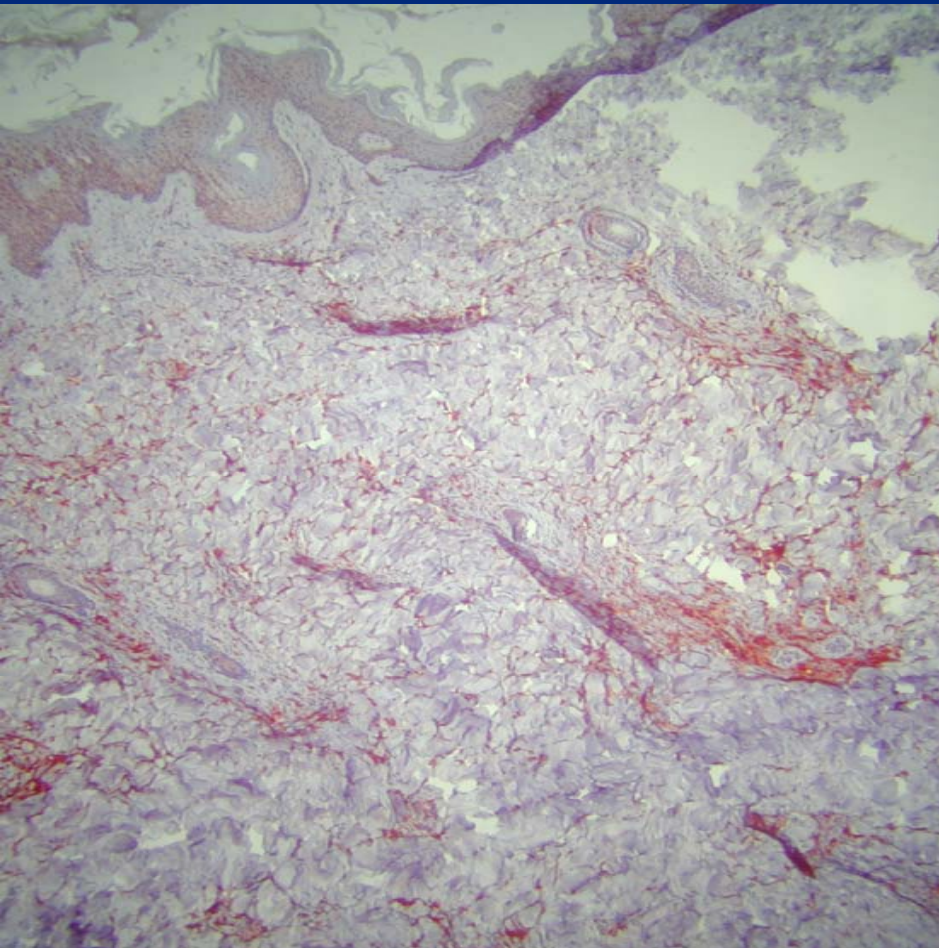
CD 30



ALK



Skin CD30 & ALK

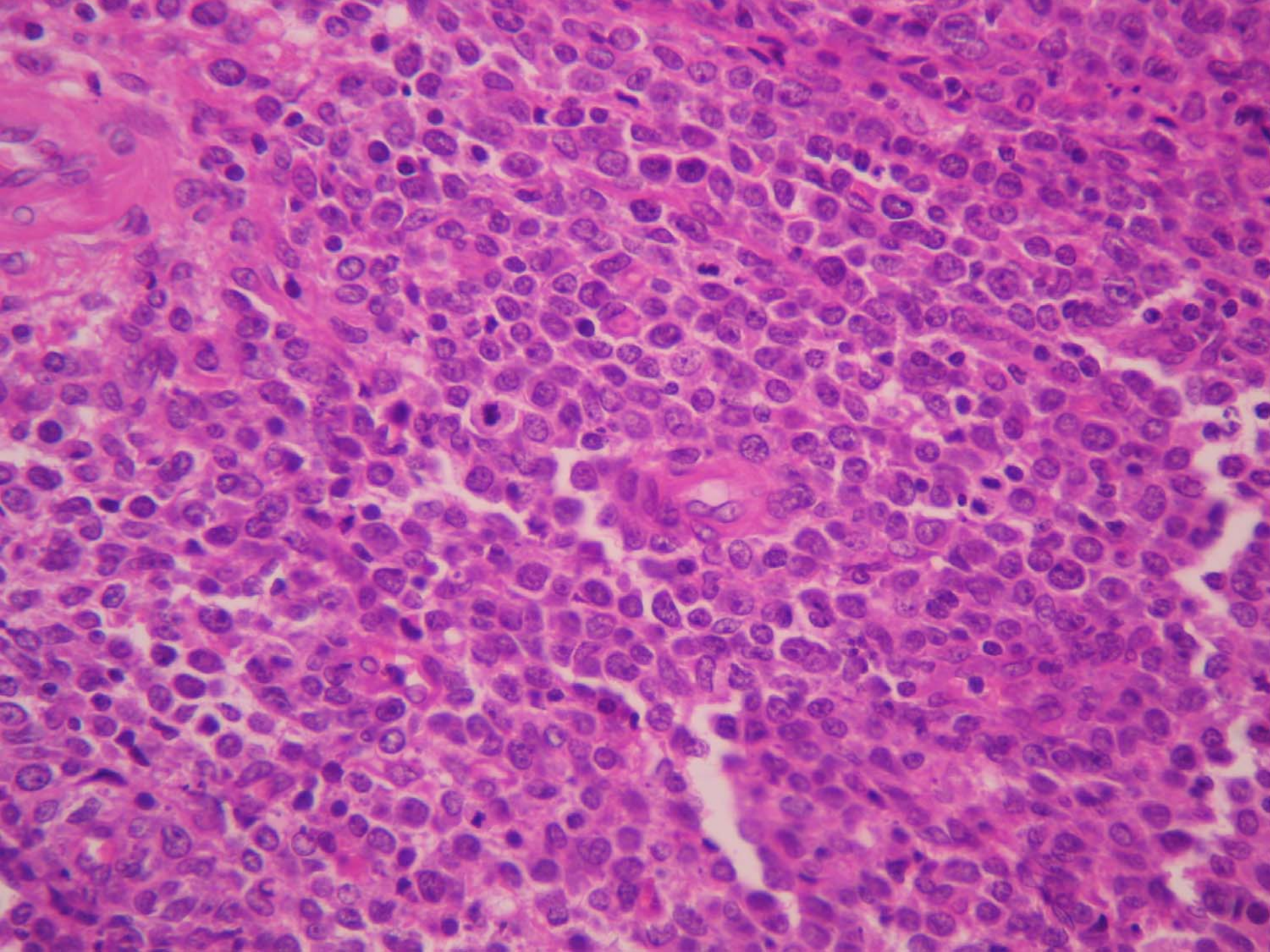


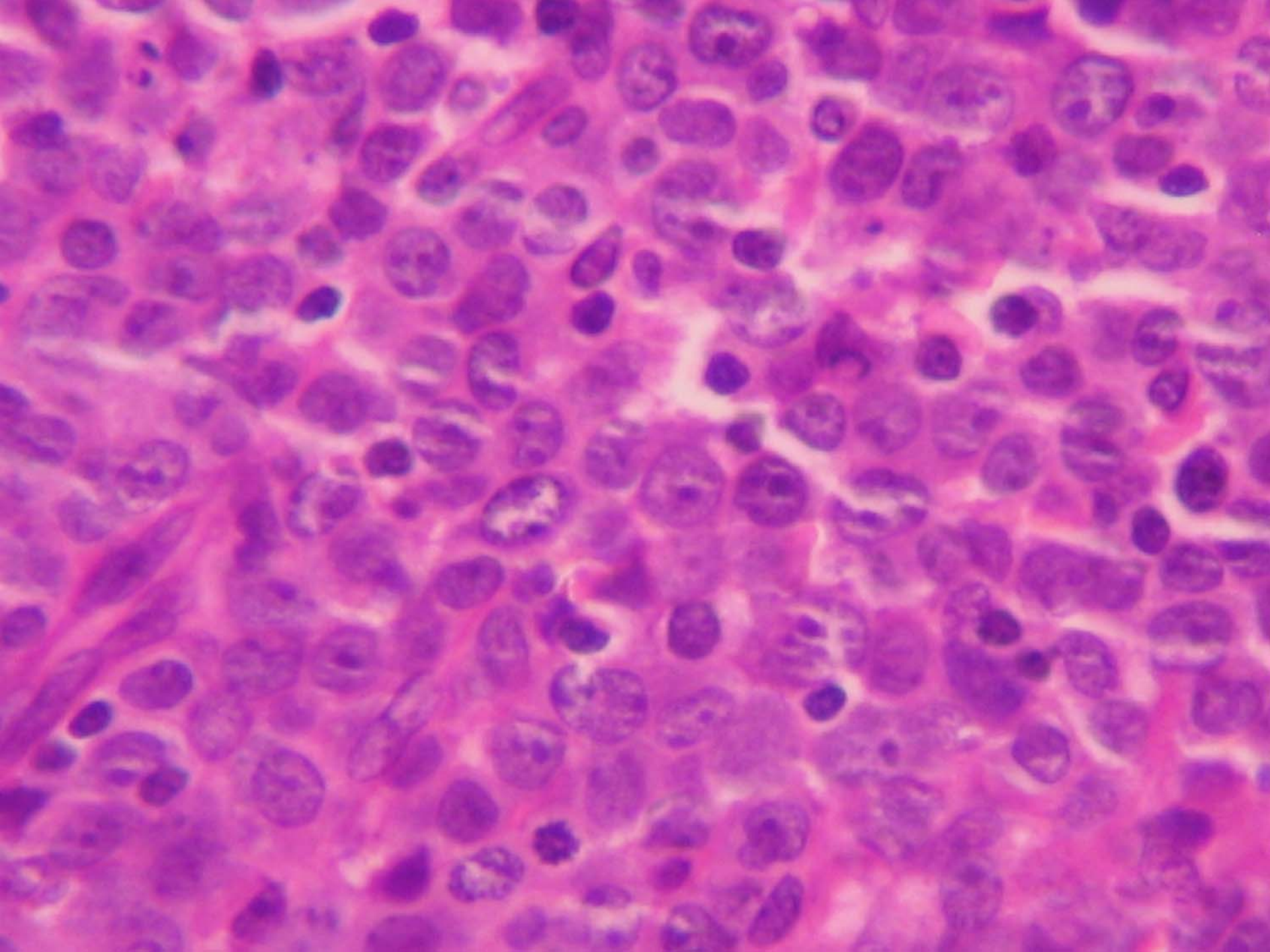
Diagnosis

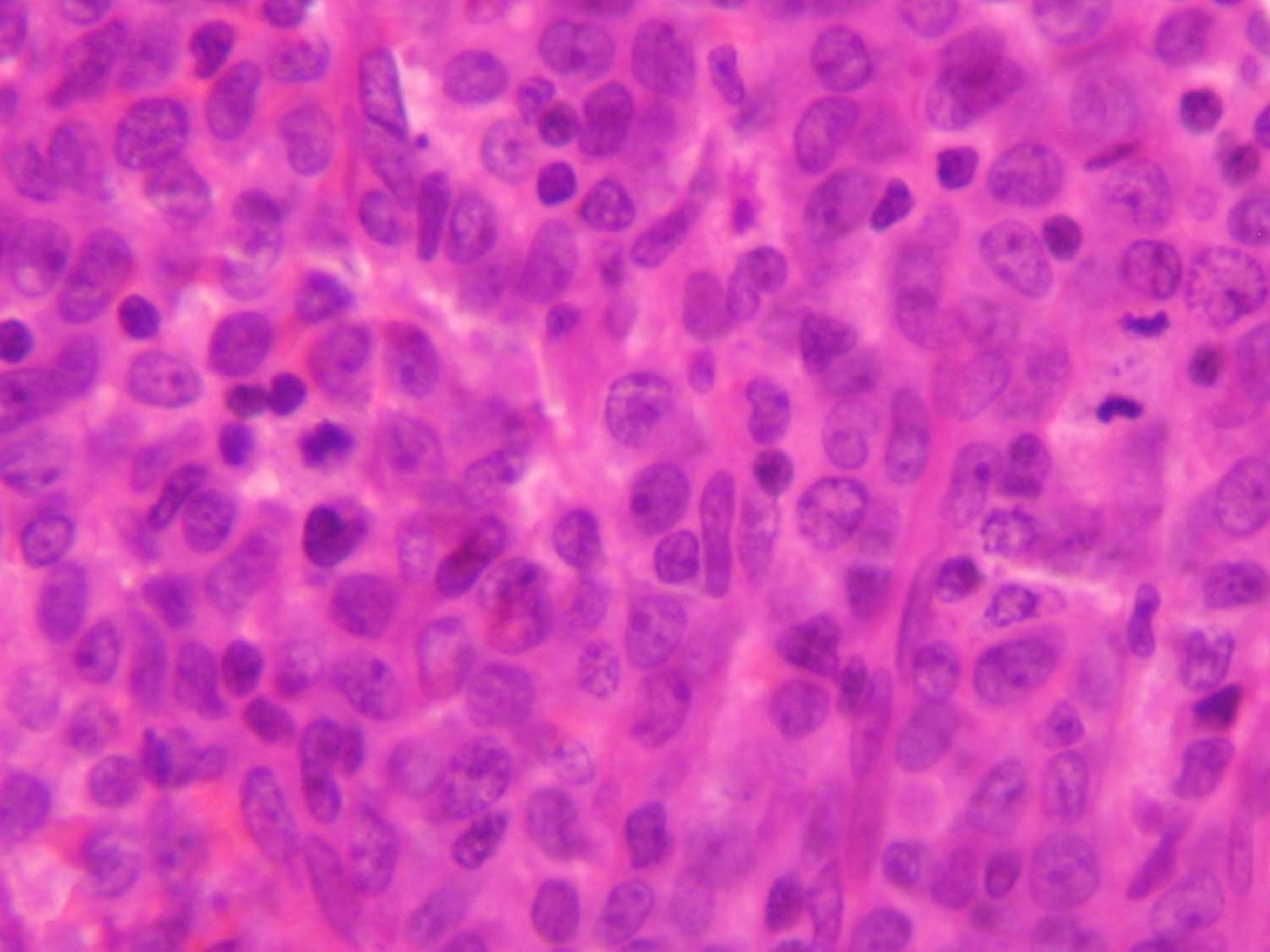
- Large Anaplastic Cell Lymphoma **Systemic**,
conventional,
CD 30 positive ALK positive and T-Cell
phenotype

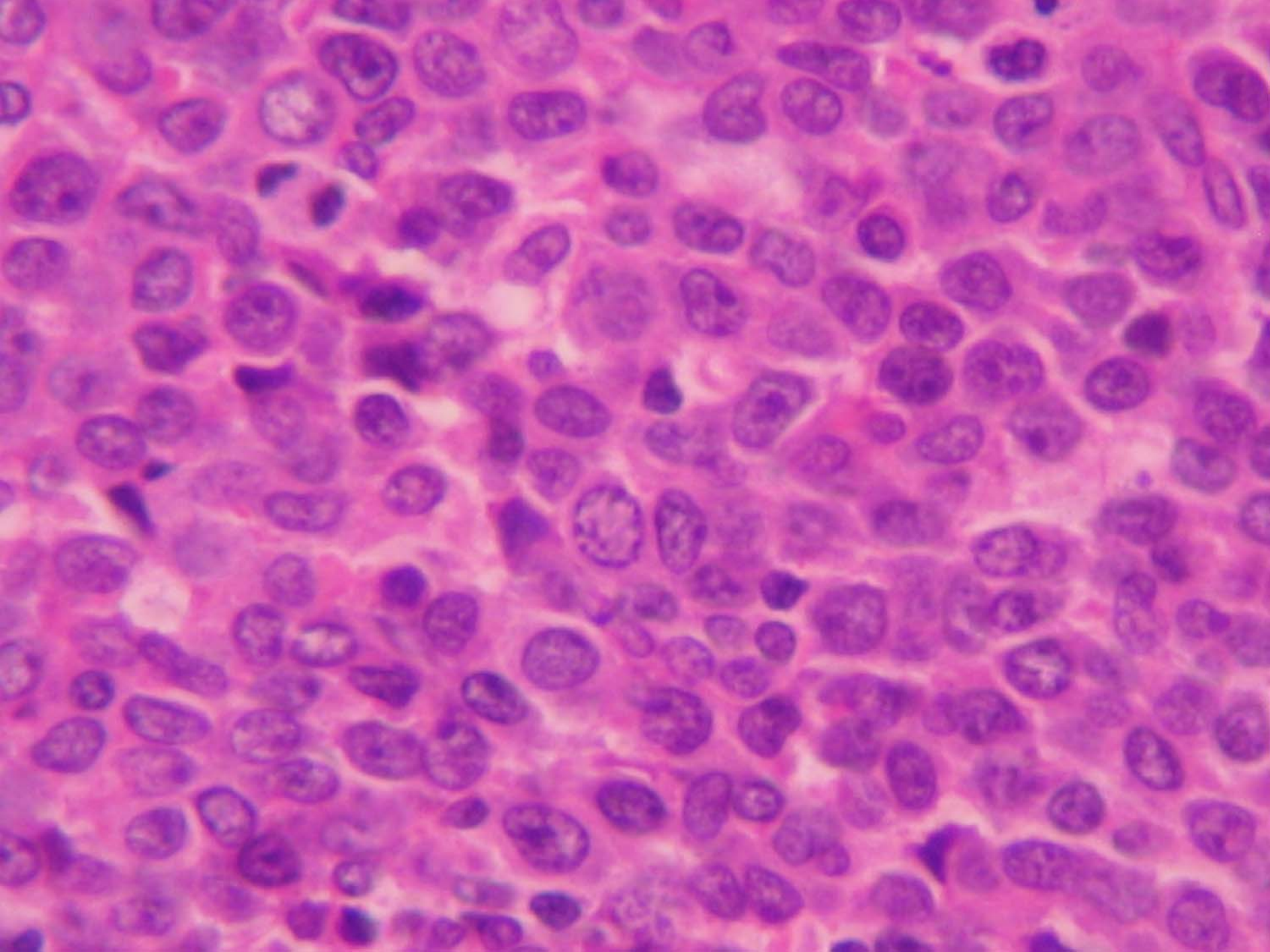
Case 2 / 0670714

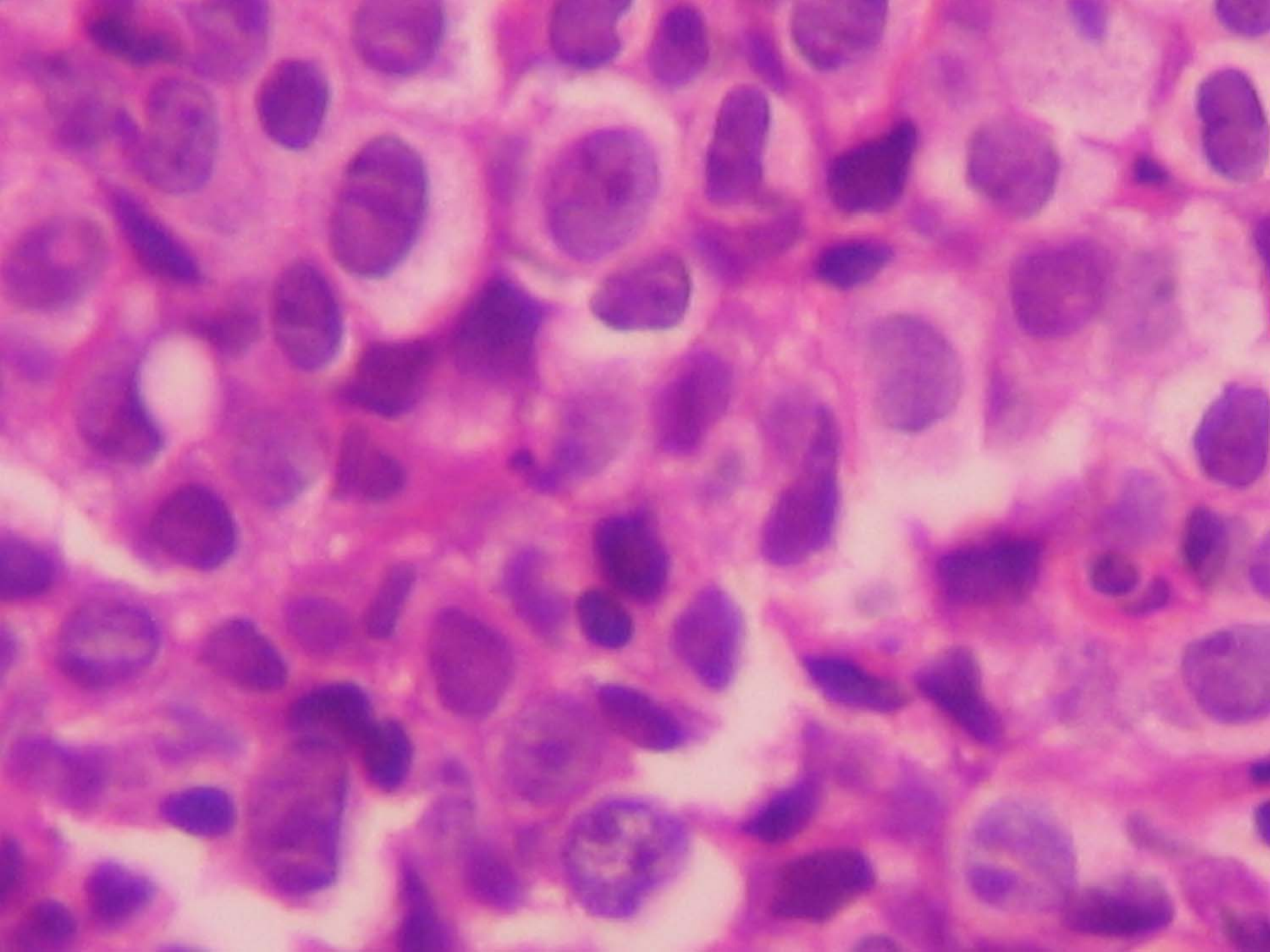
- 65 years old male
- Inguinal lymph node
- Received four paraffin blocks for confirmation



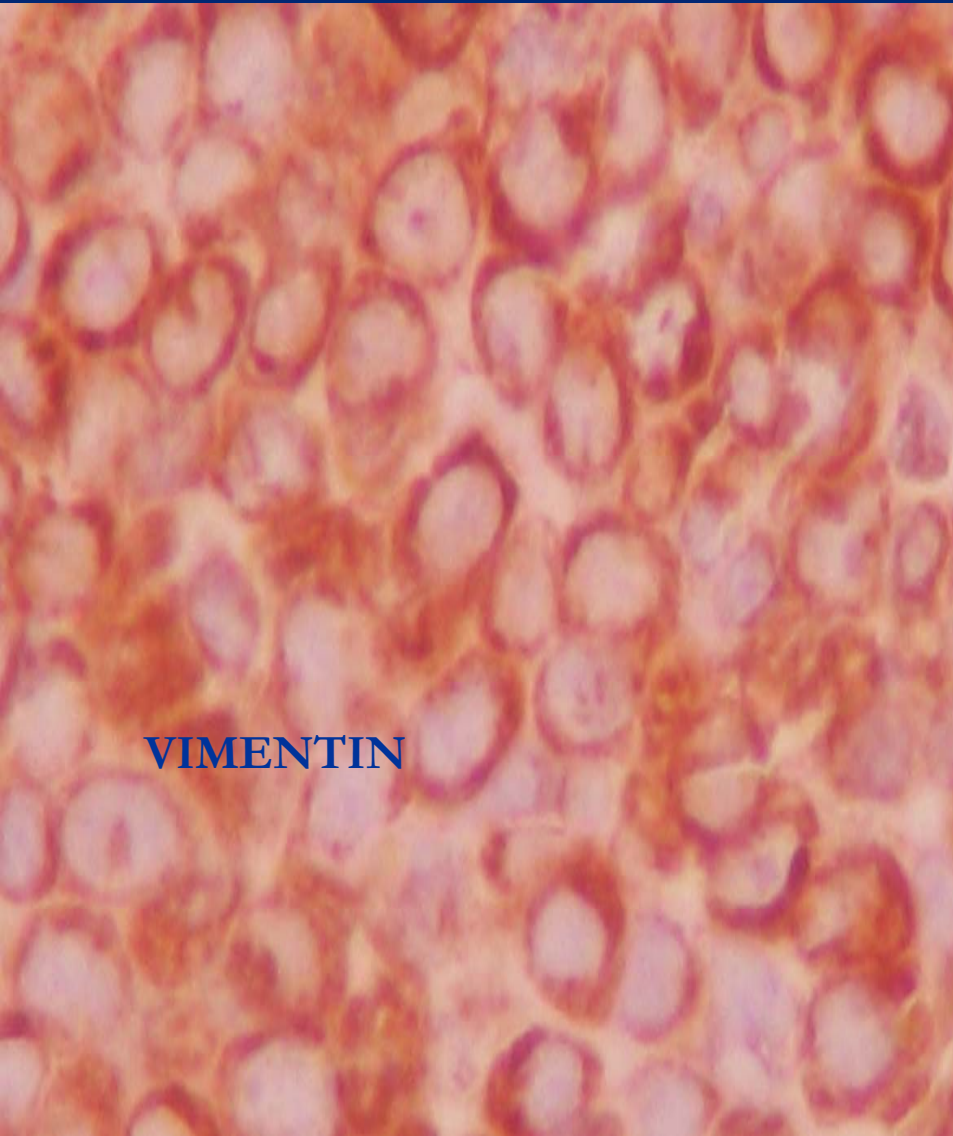




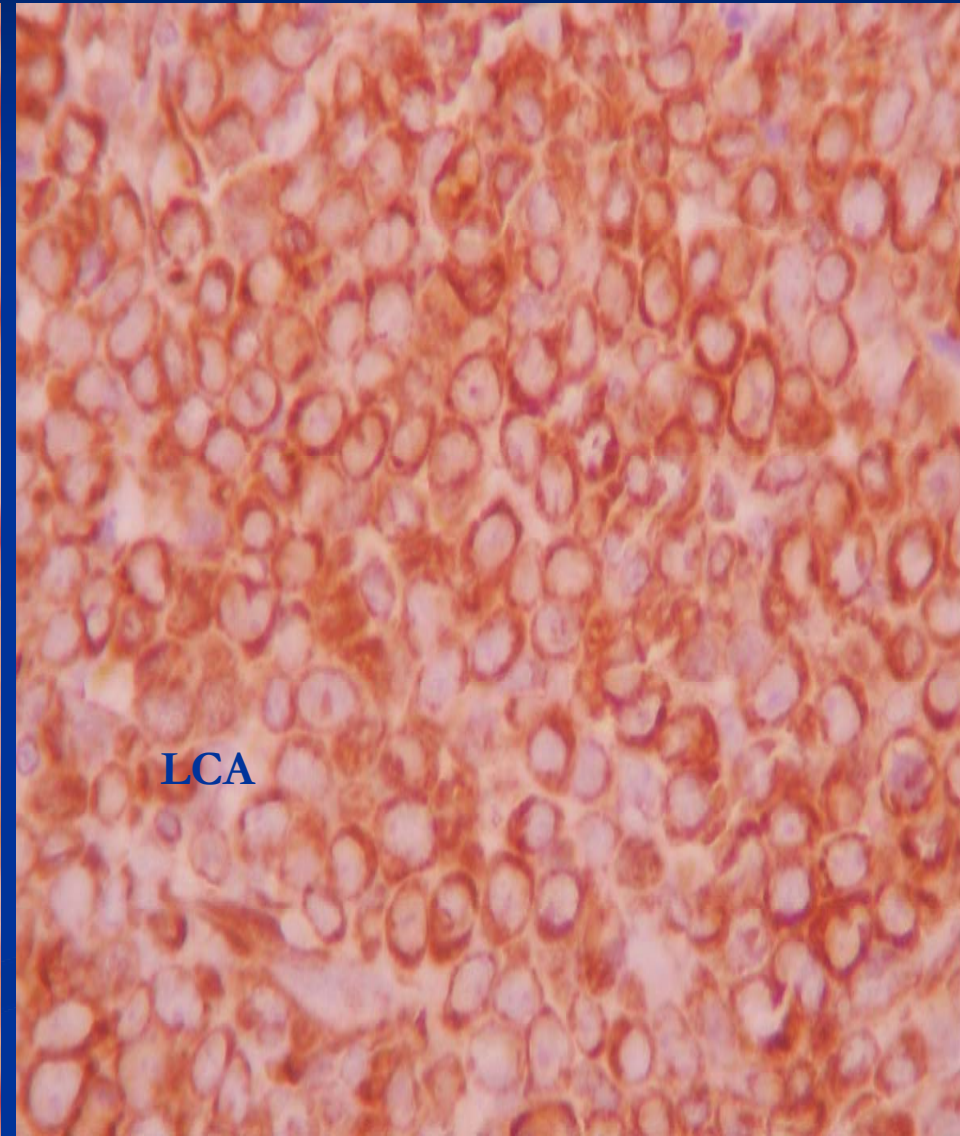


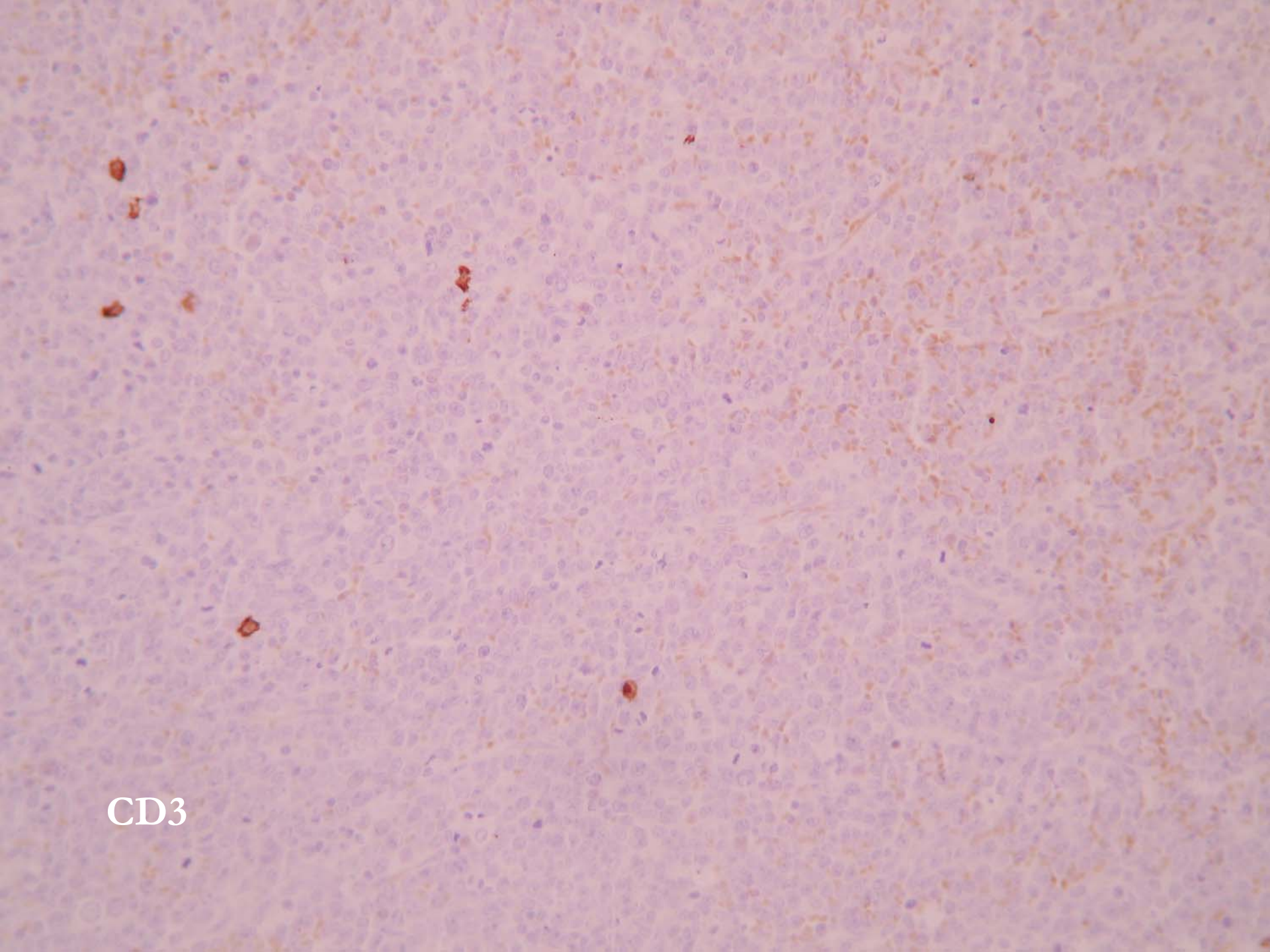


Vimentin

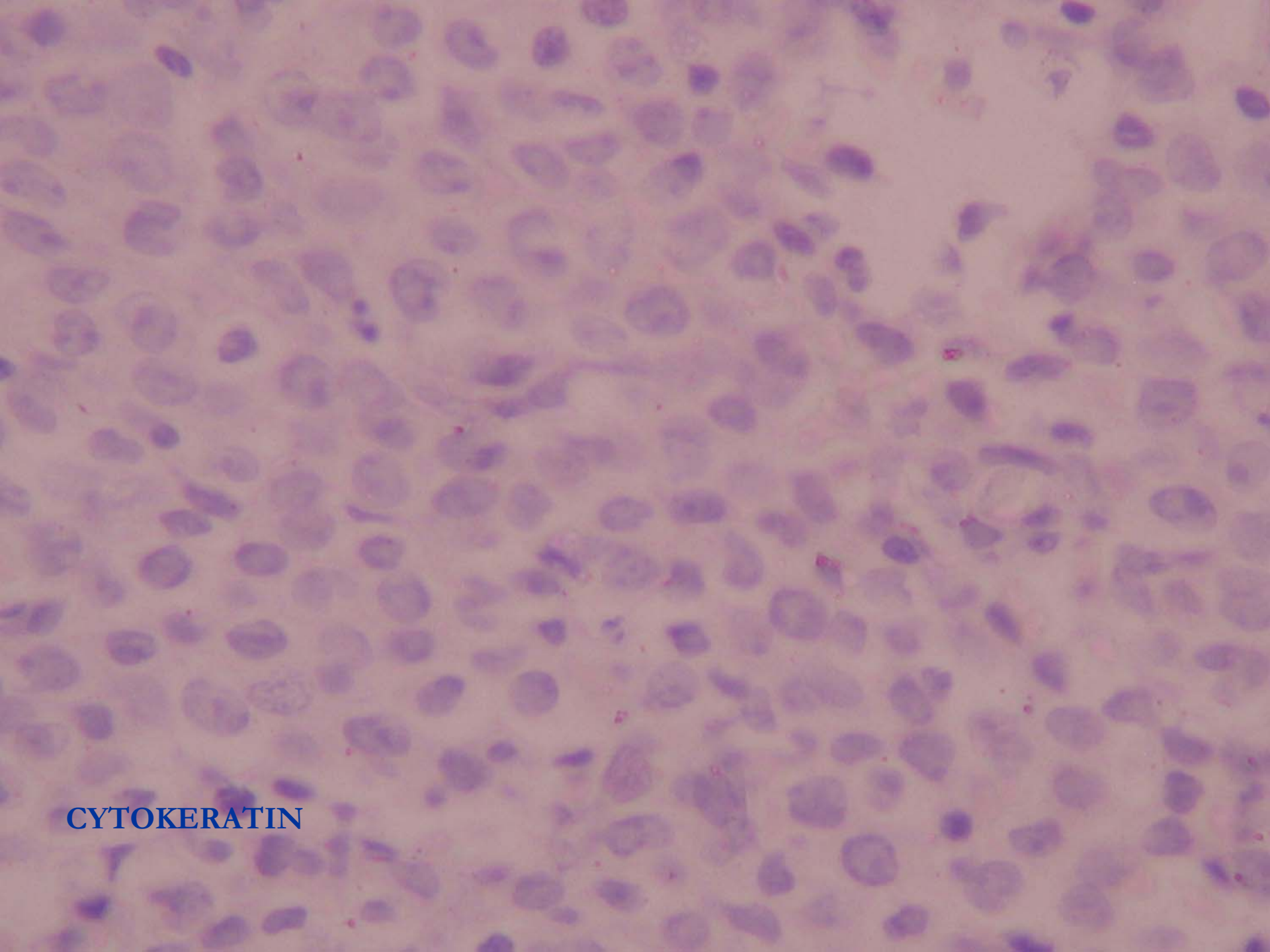


LCA

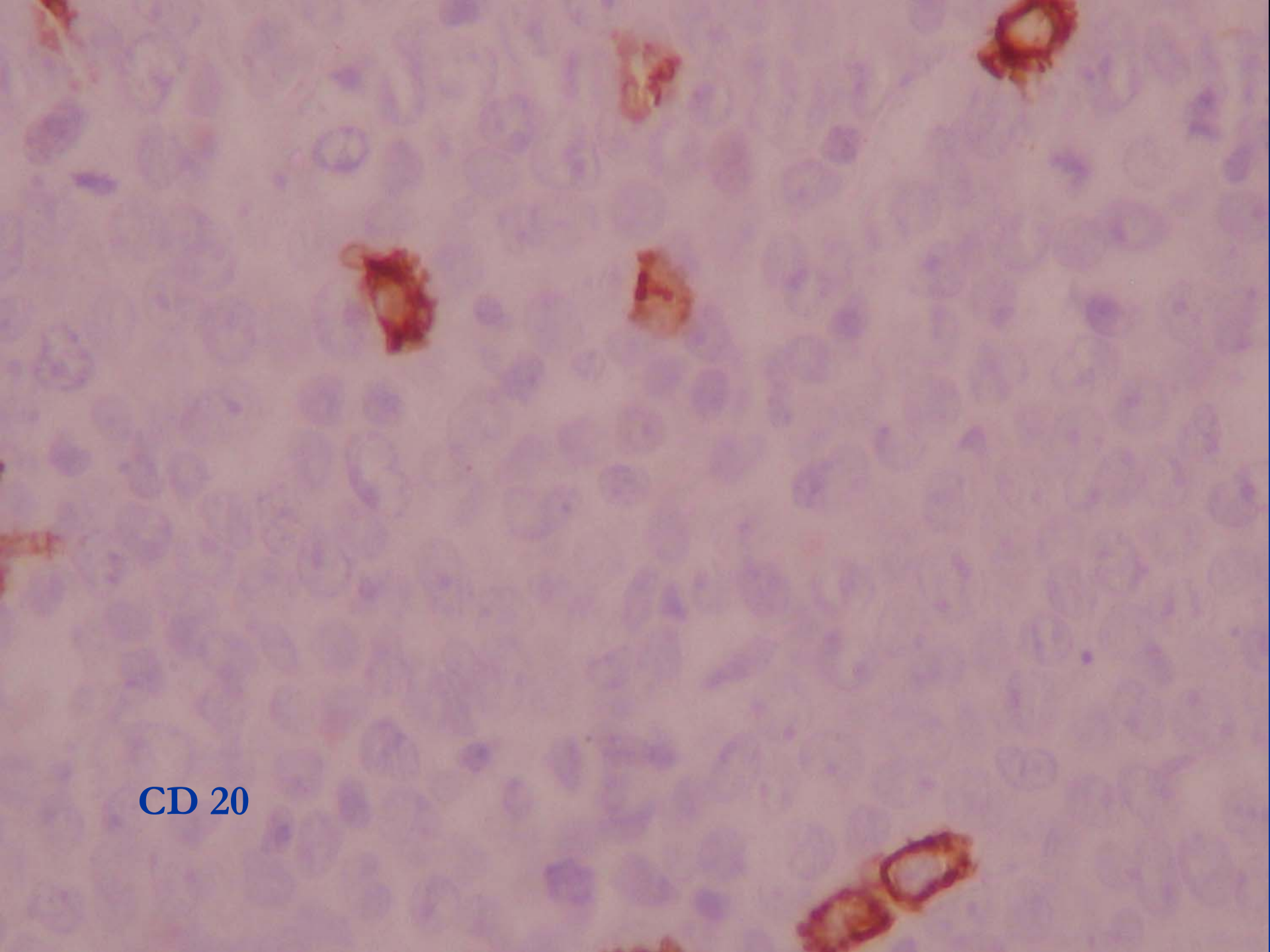




CD3



CYTOKERATIN

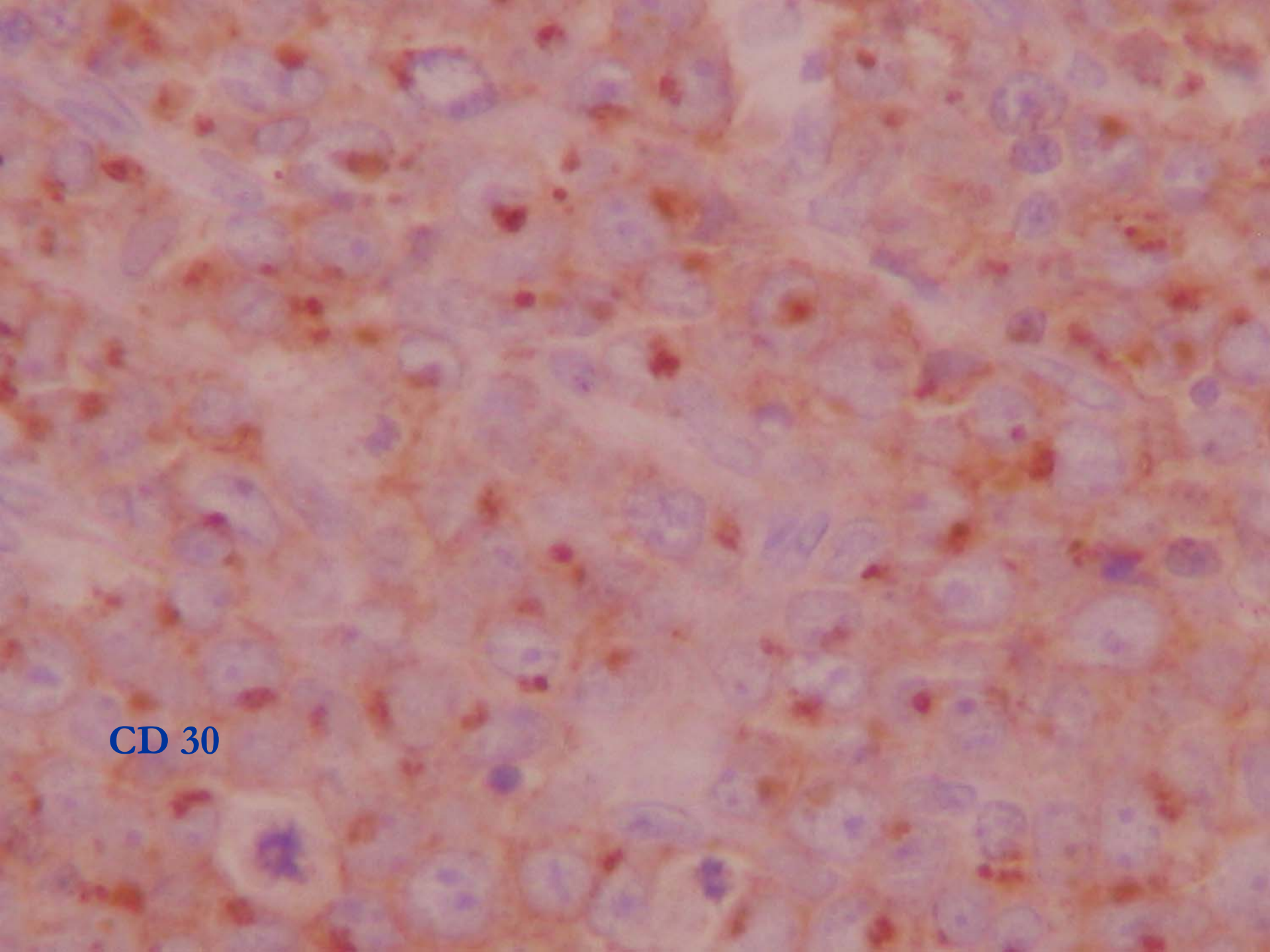


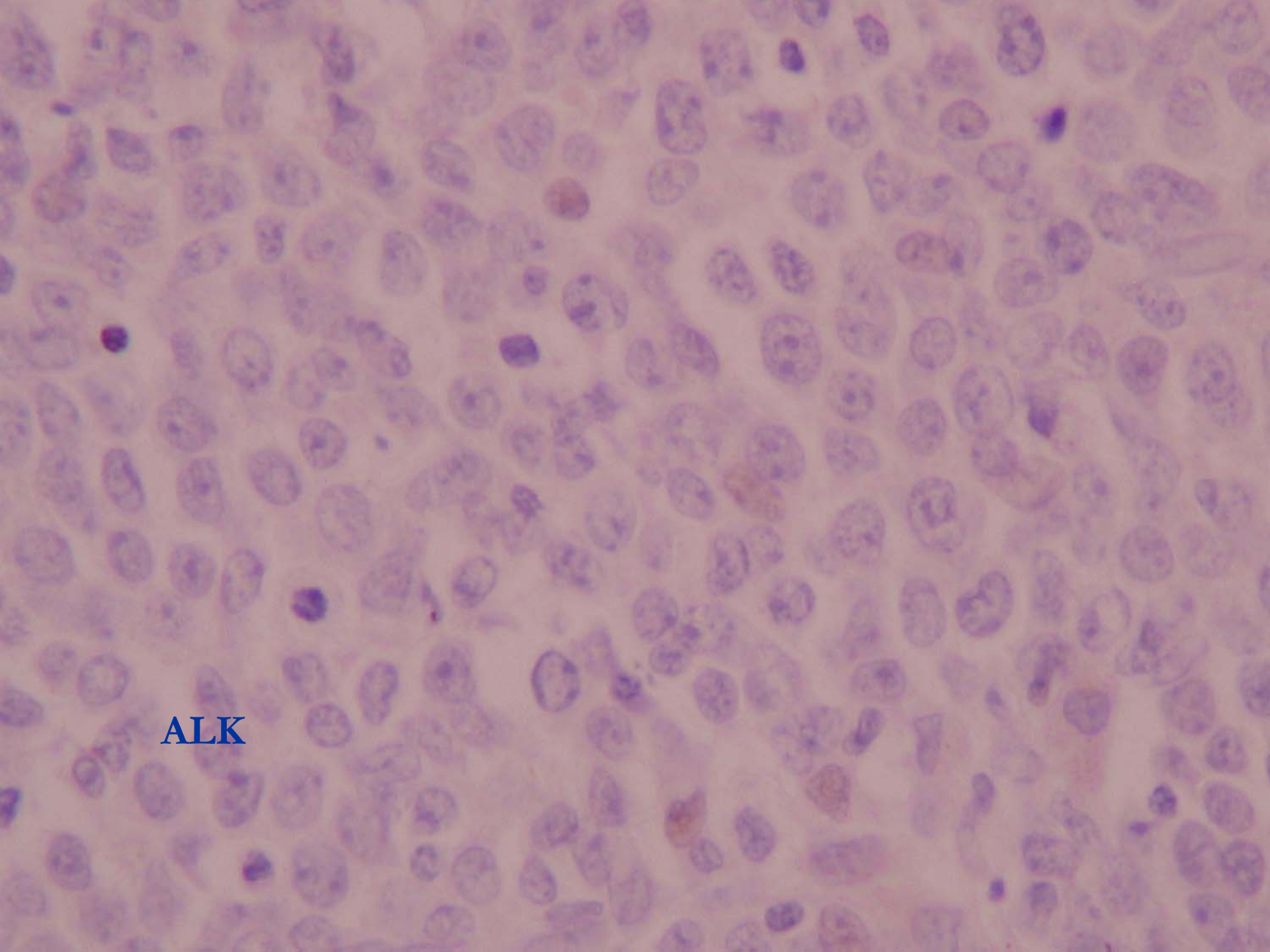
CD 20



CD 30

CD 30





ALK

DIAGNOSIS

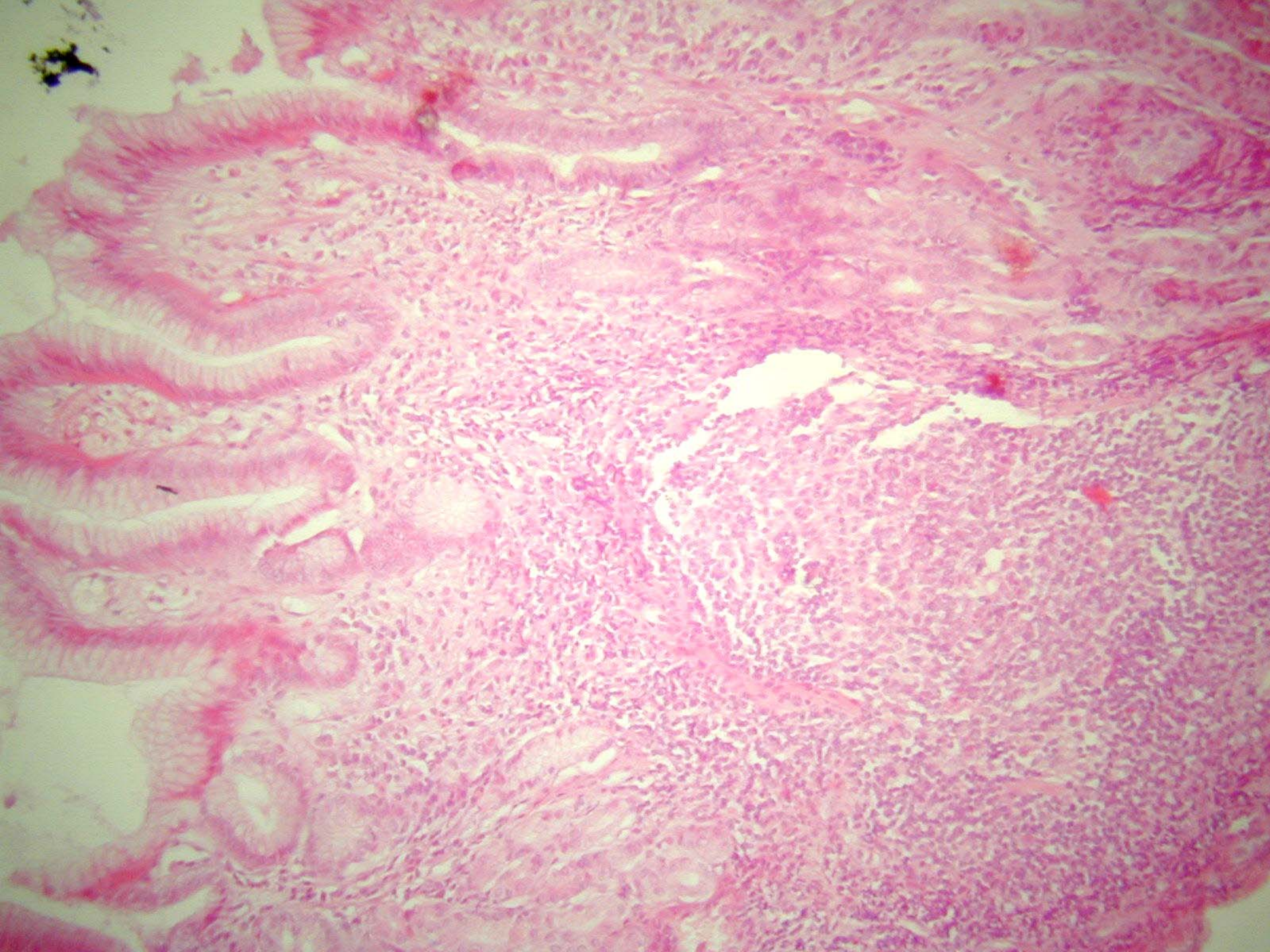
- Anaplastic Large Cell Lymphoma, Small cell variant **Nodal**

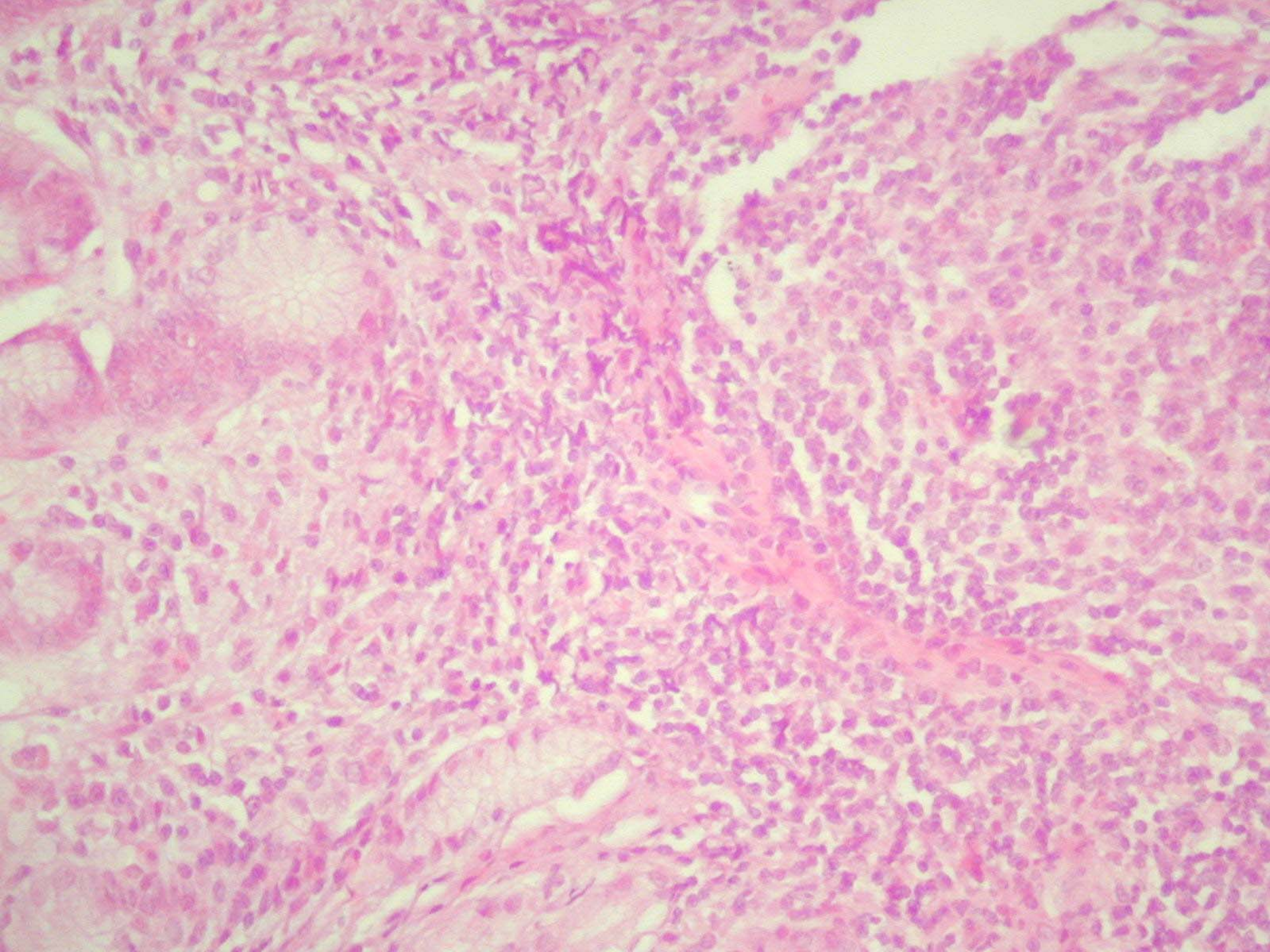
CD30 positive, ALK negative

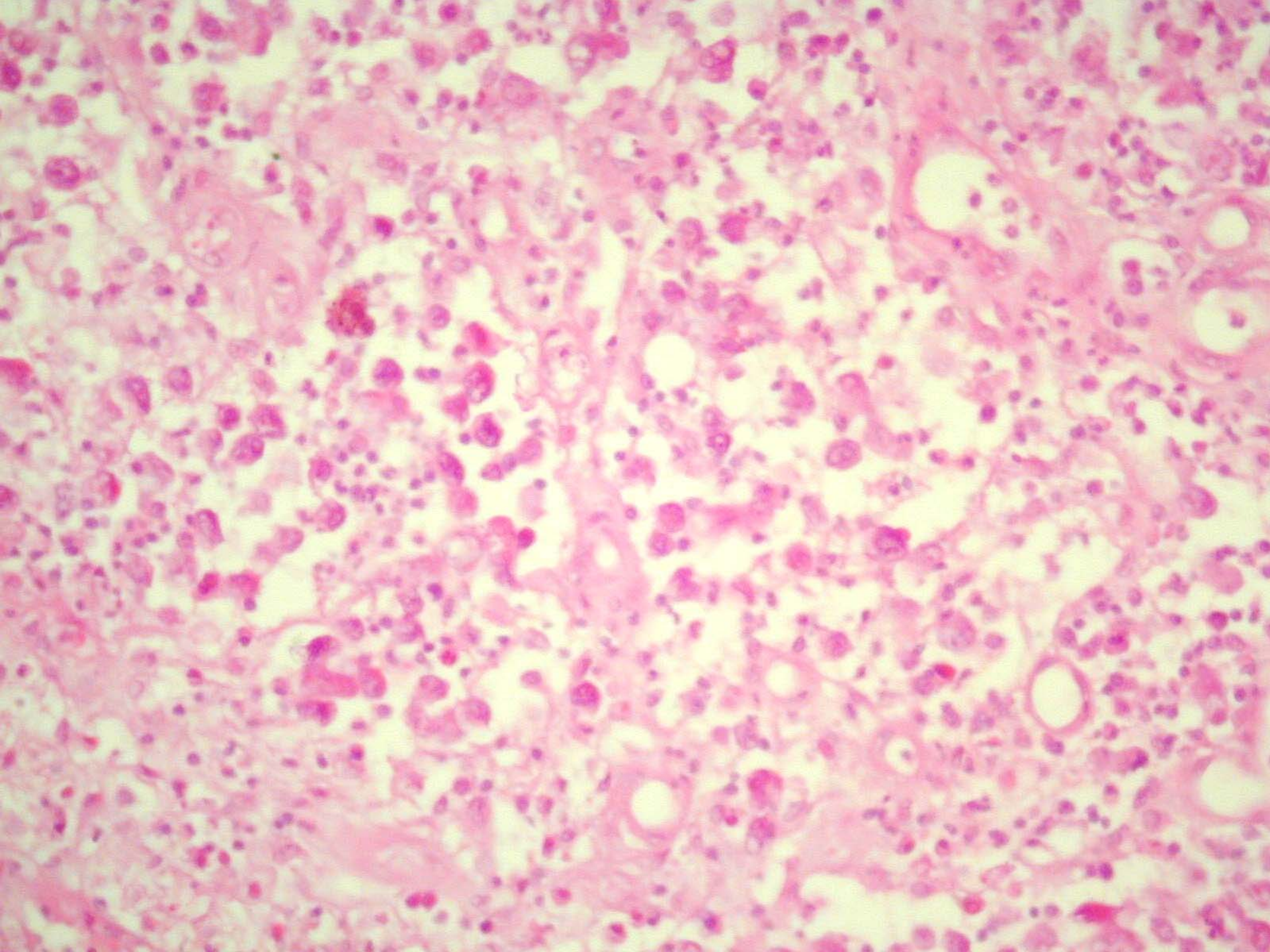
Case 3

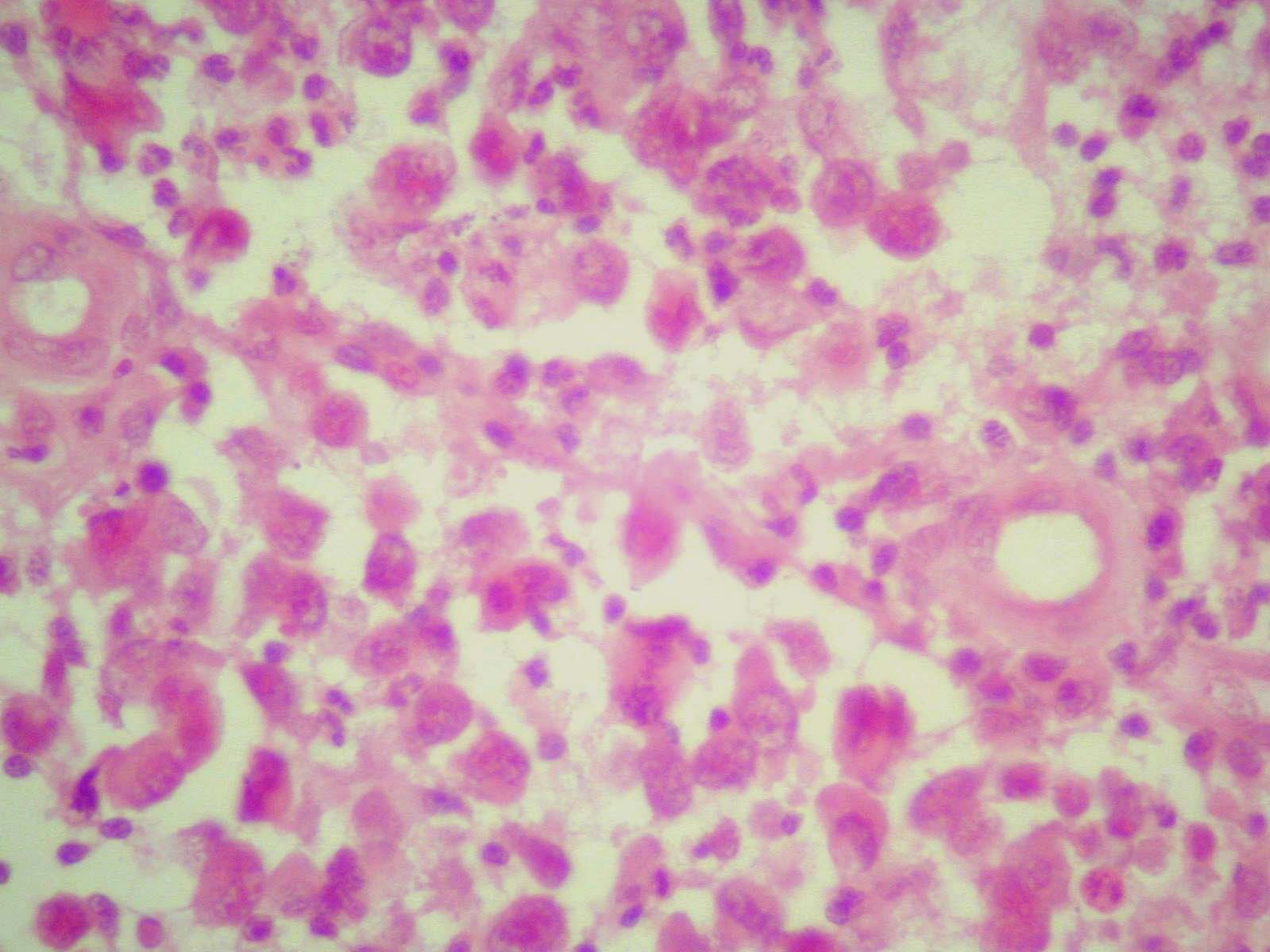
Received: One glass slide + One paraffin block for confirmation (previous diagnosis: Adenoca)

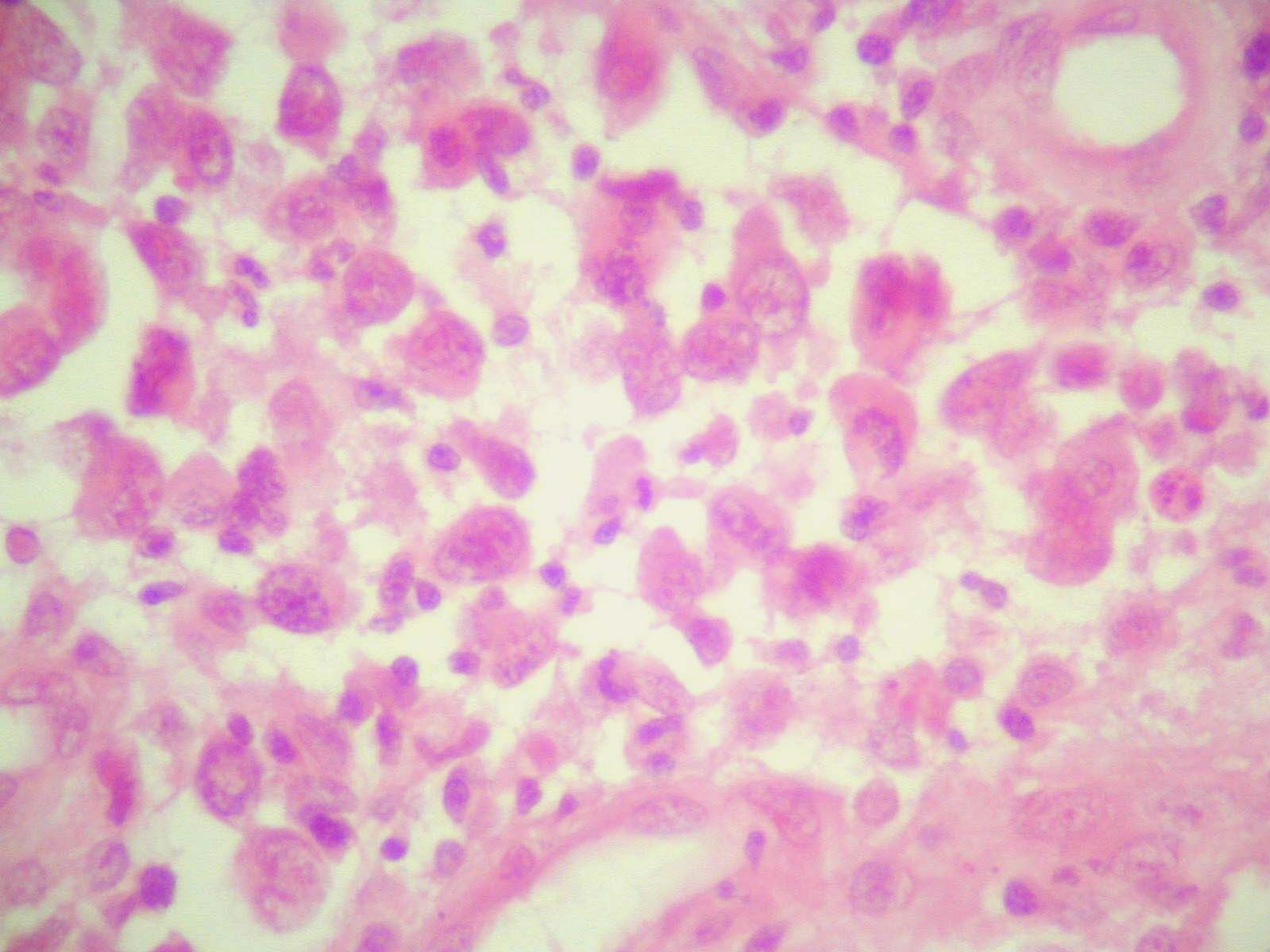
- 12 year-old-boy
- clinically, loss weight
- No skin rash
- Upper GI endoscopy: Mass measuring 4cm, located at the esogastric junction: biopsies
- CT Scan: periaortic lymph nodes

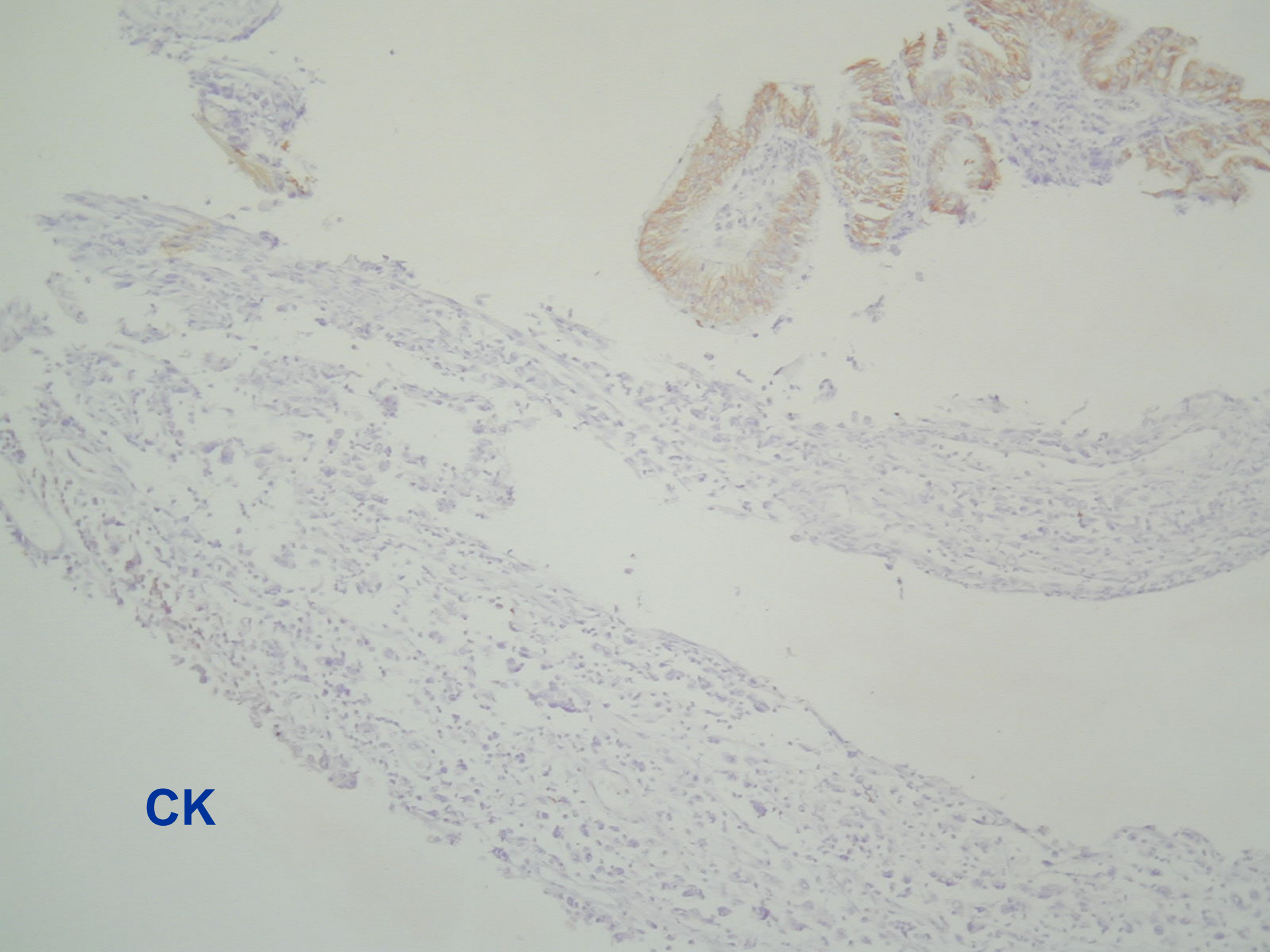




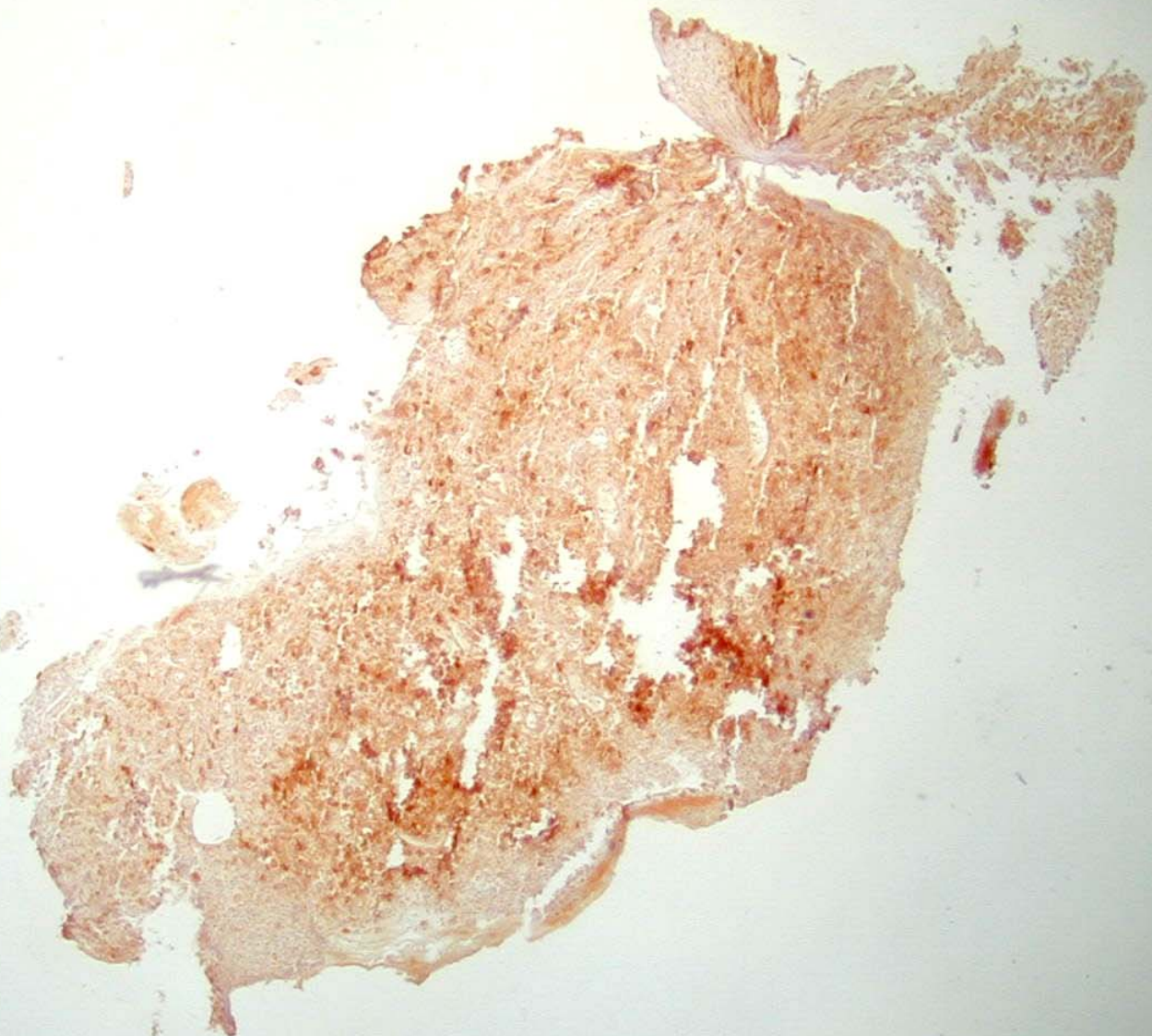
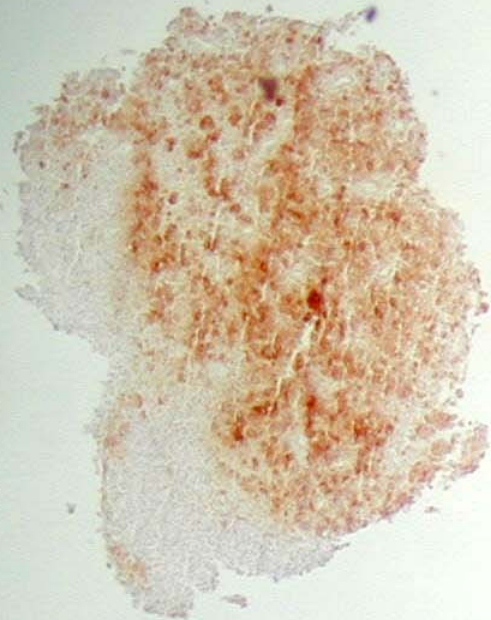



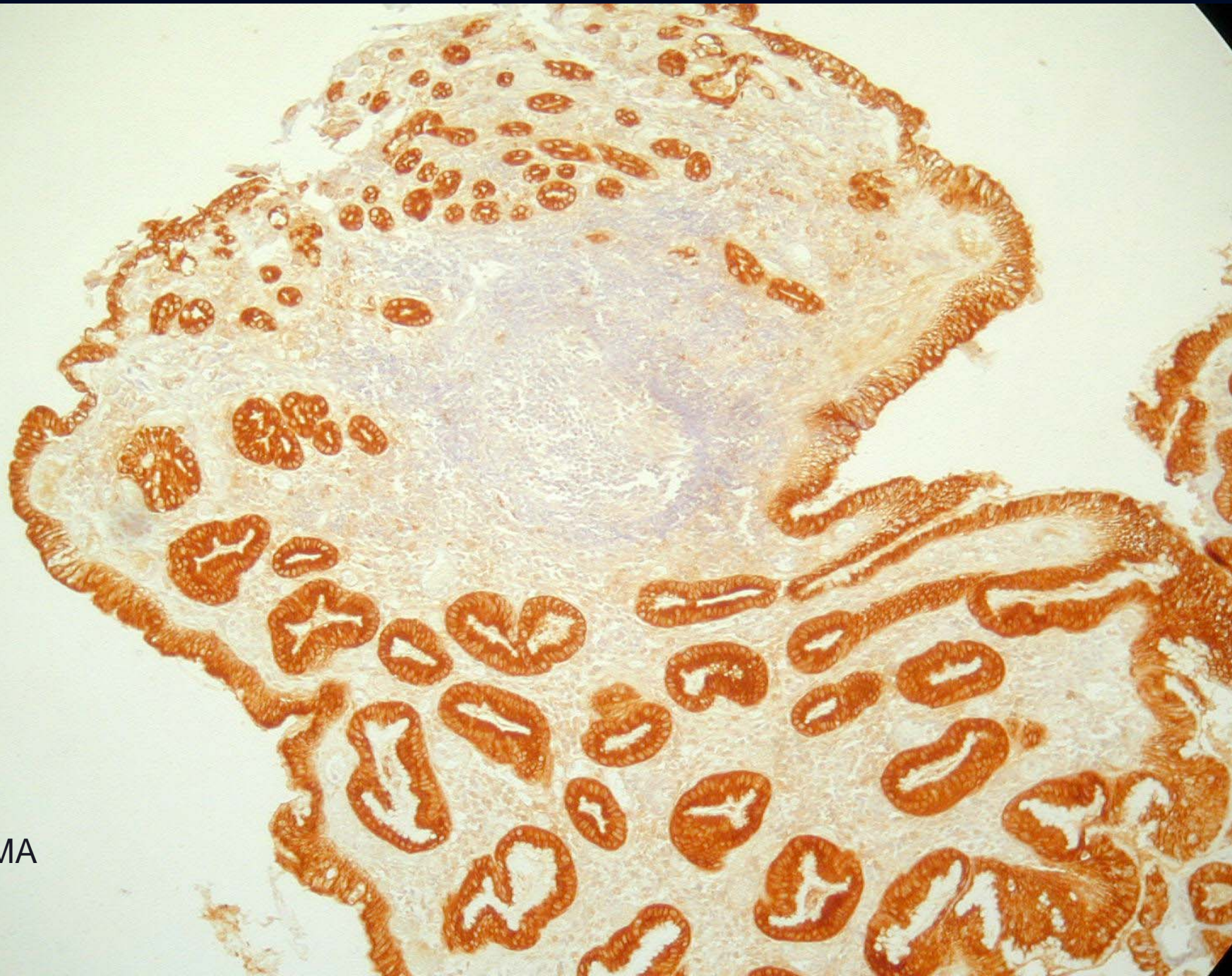




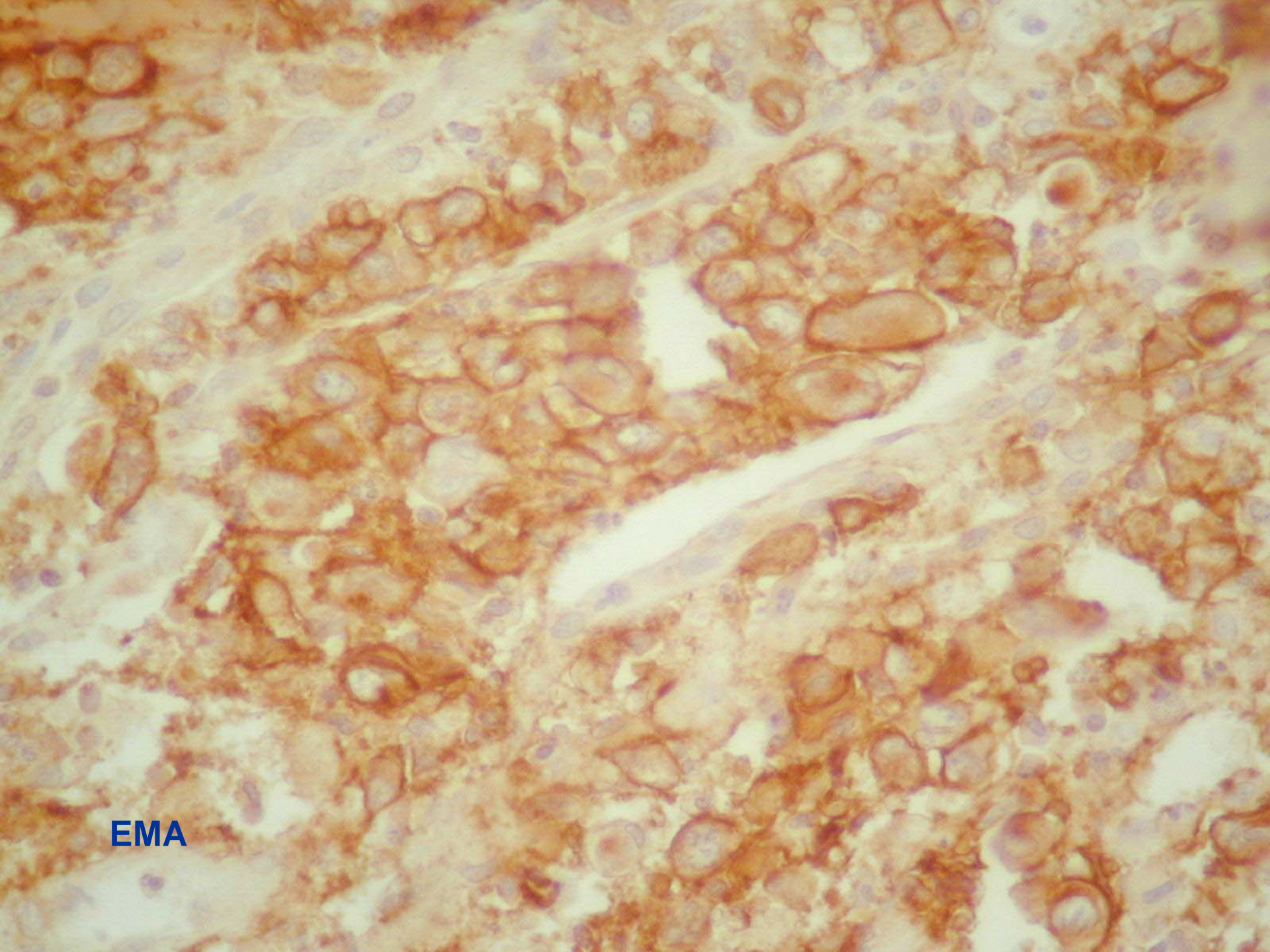
CK



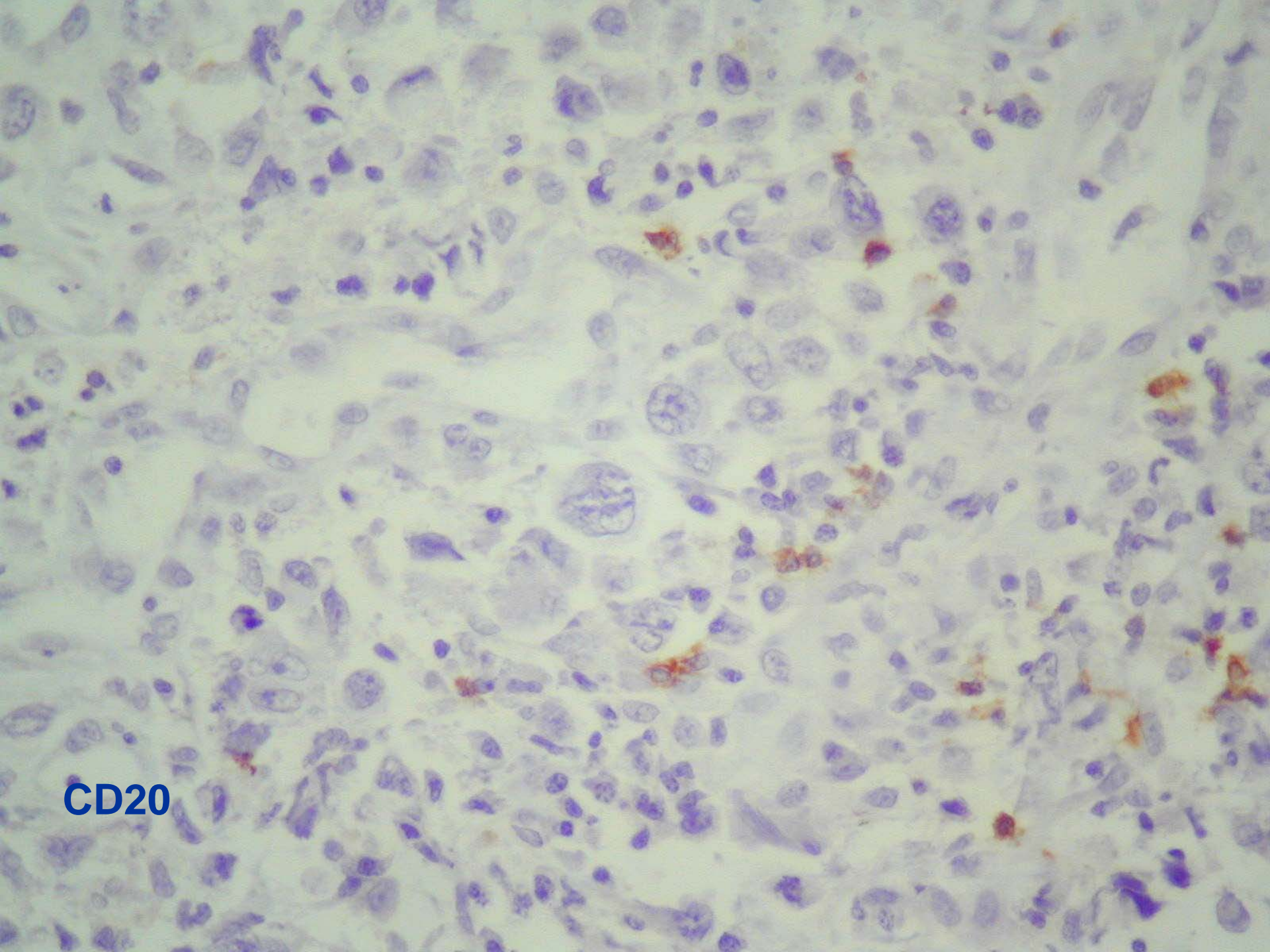
EMA



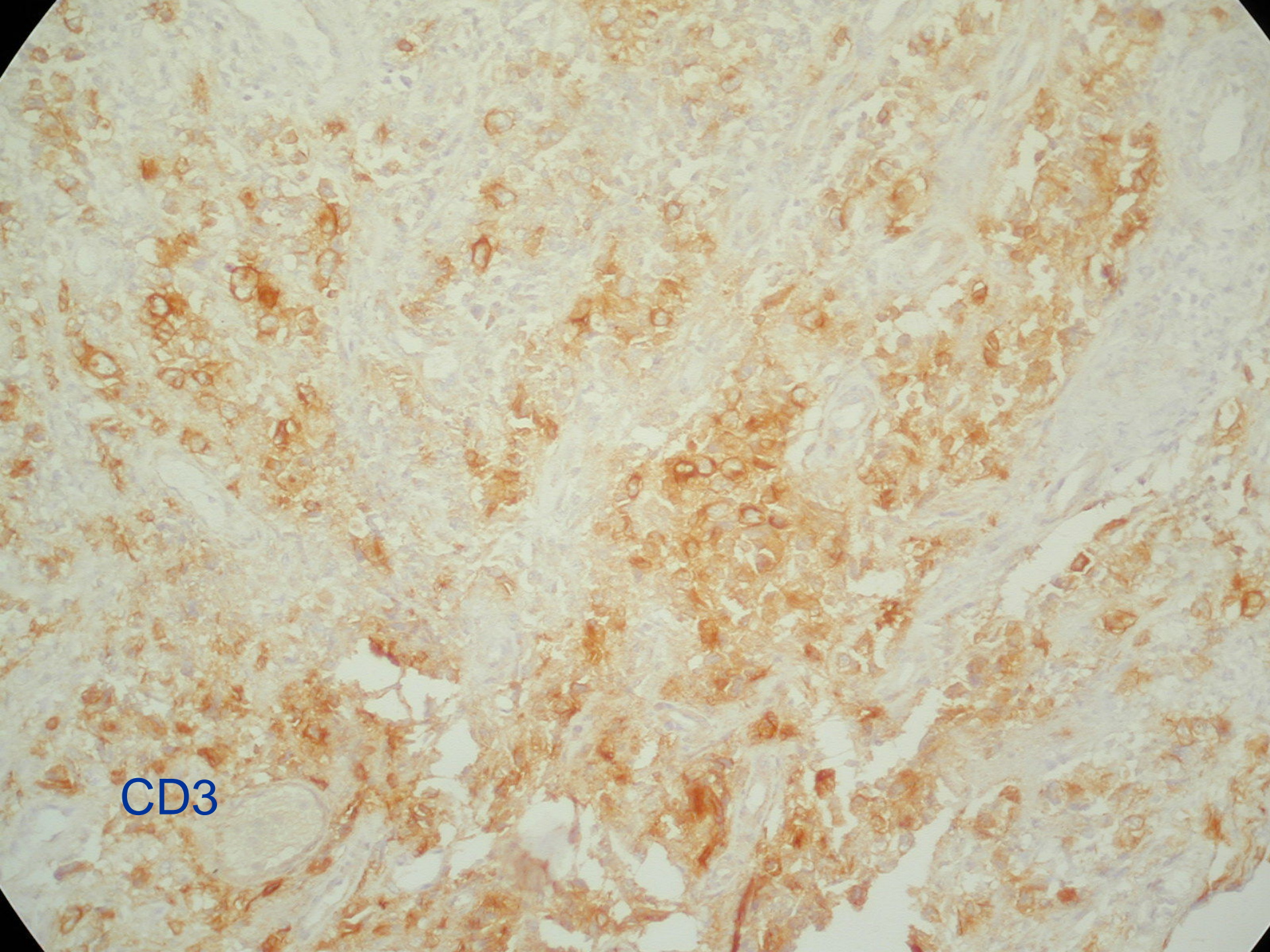
EMA



EMA

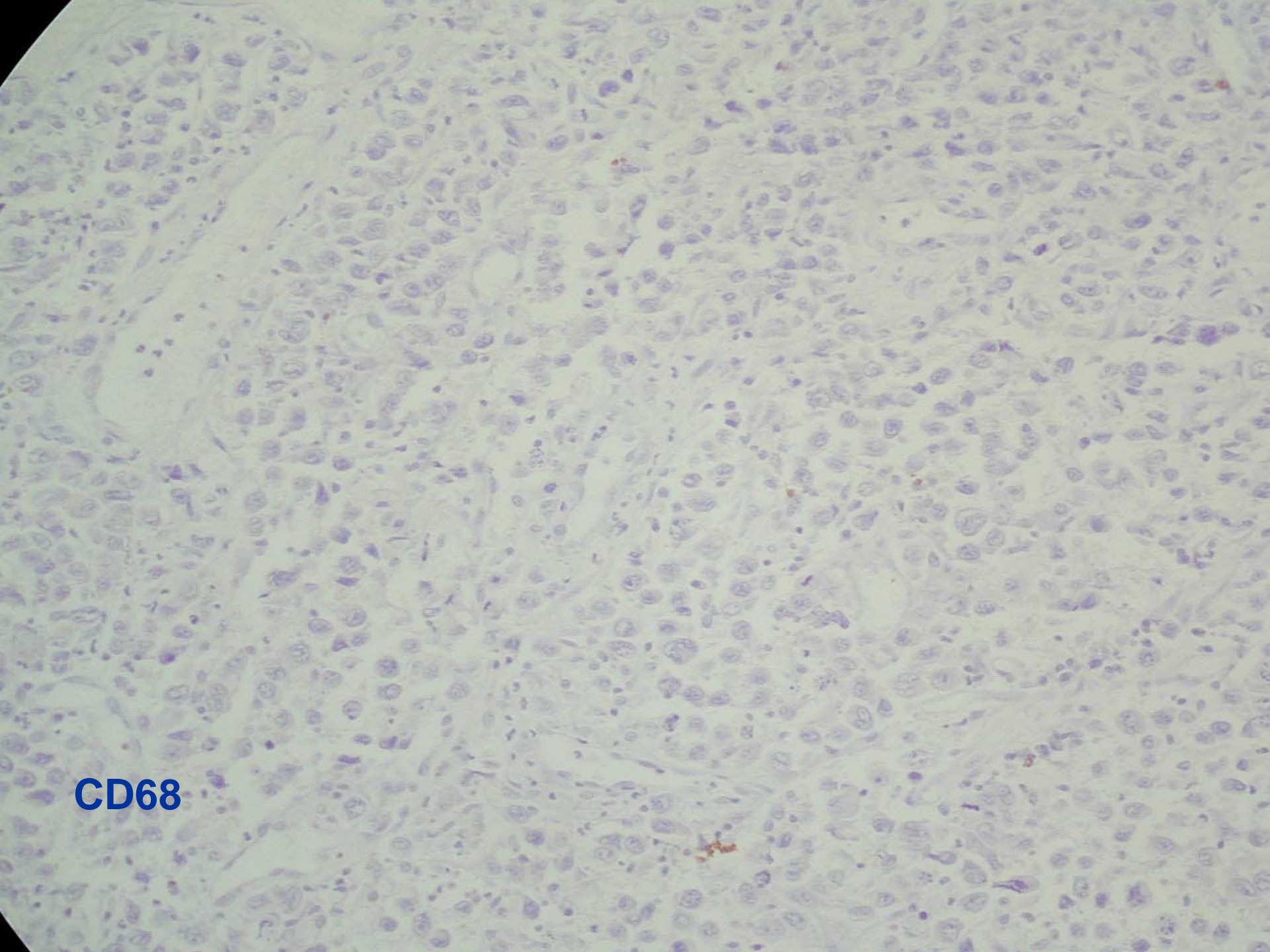


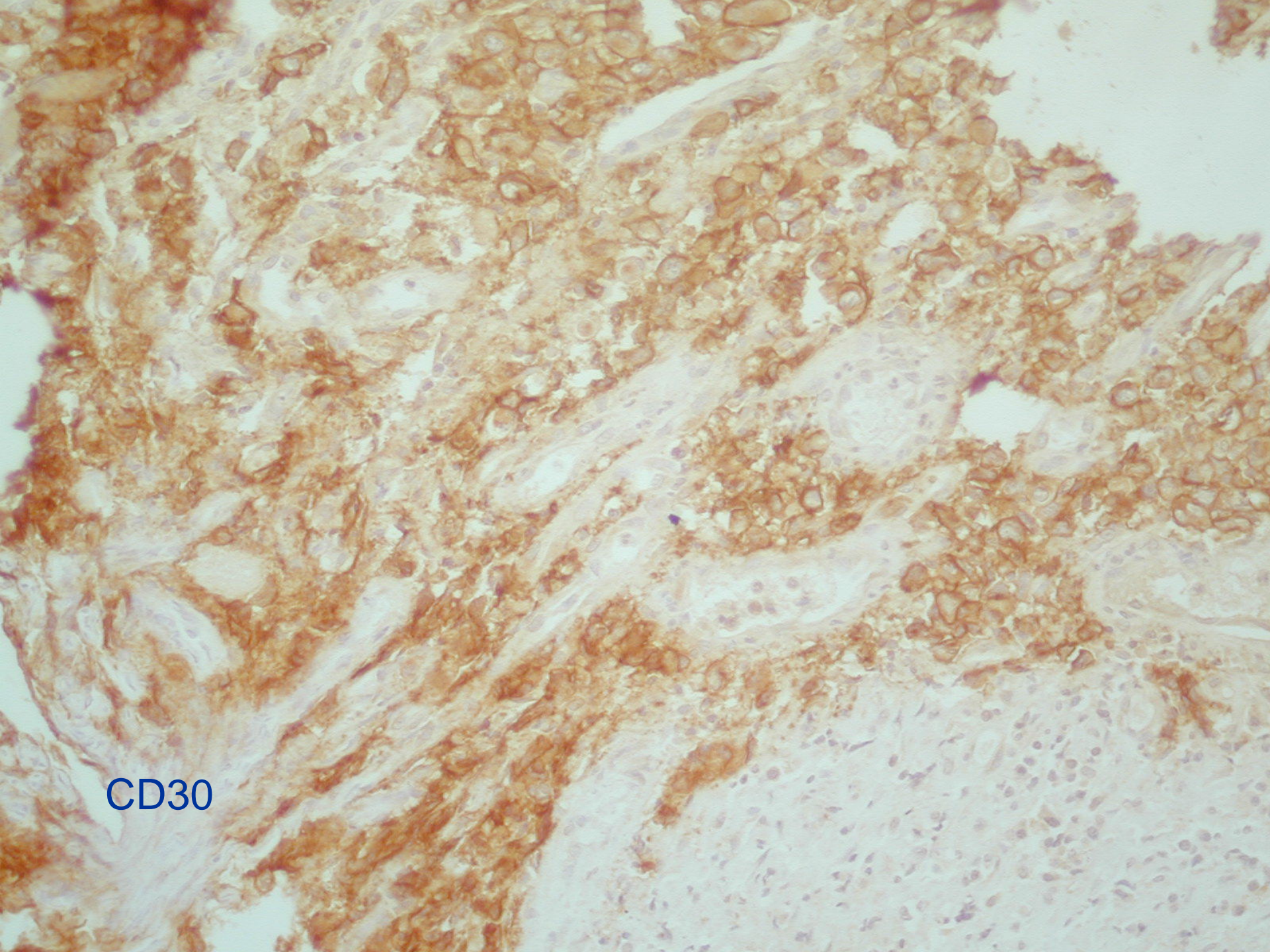
CD20



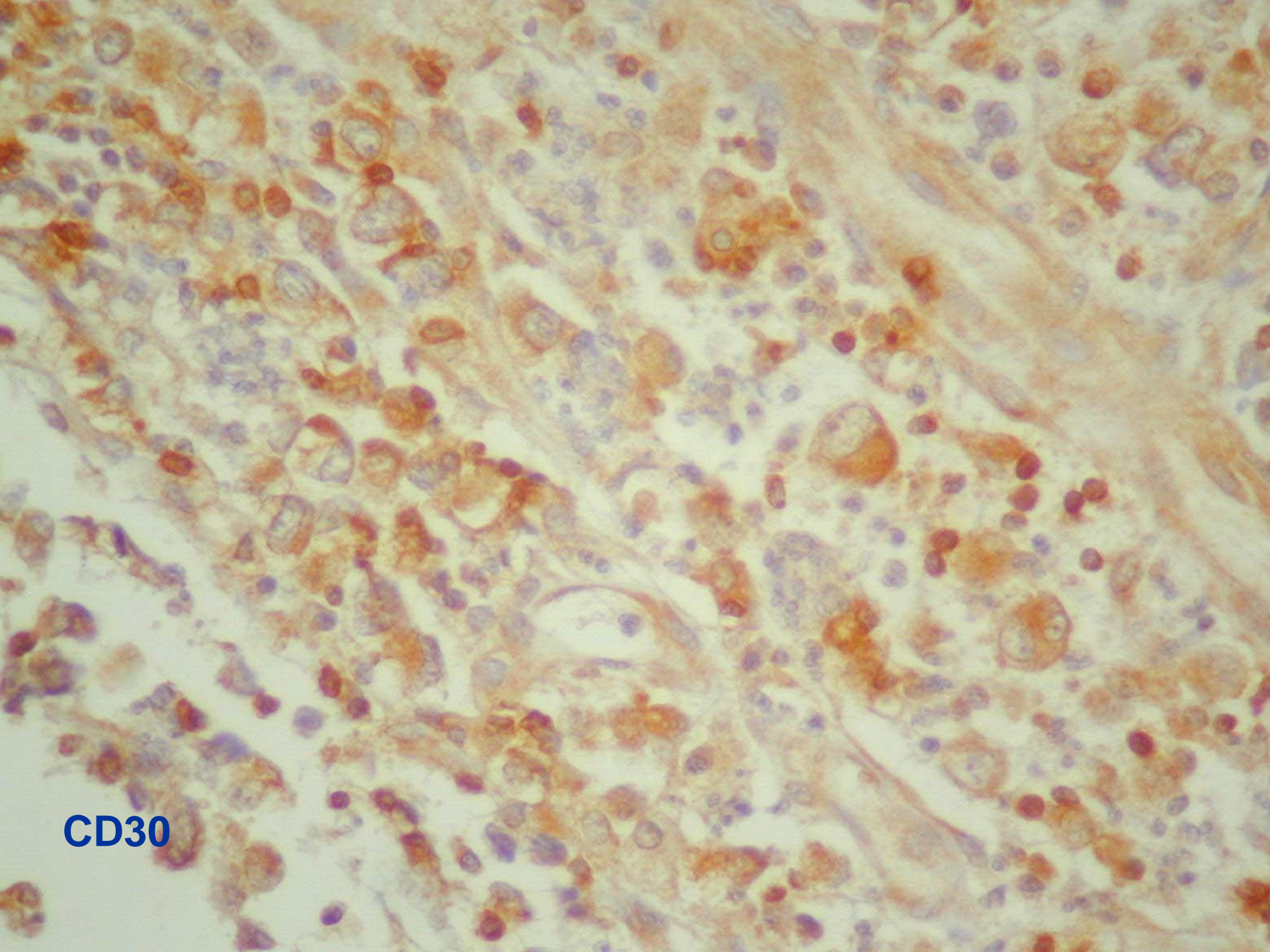
CD3

CD68

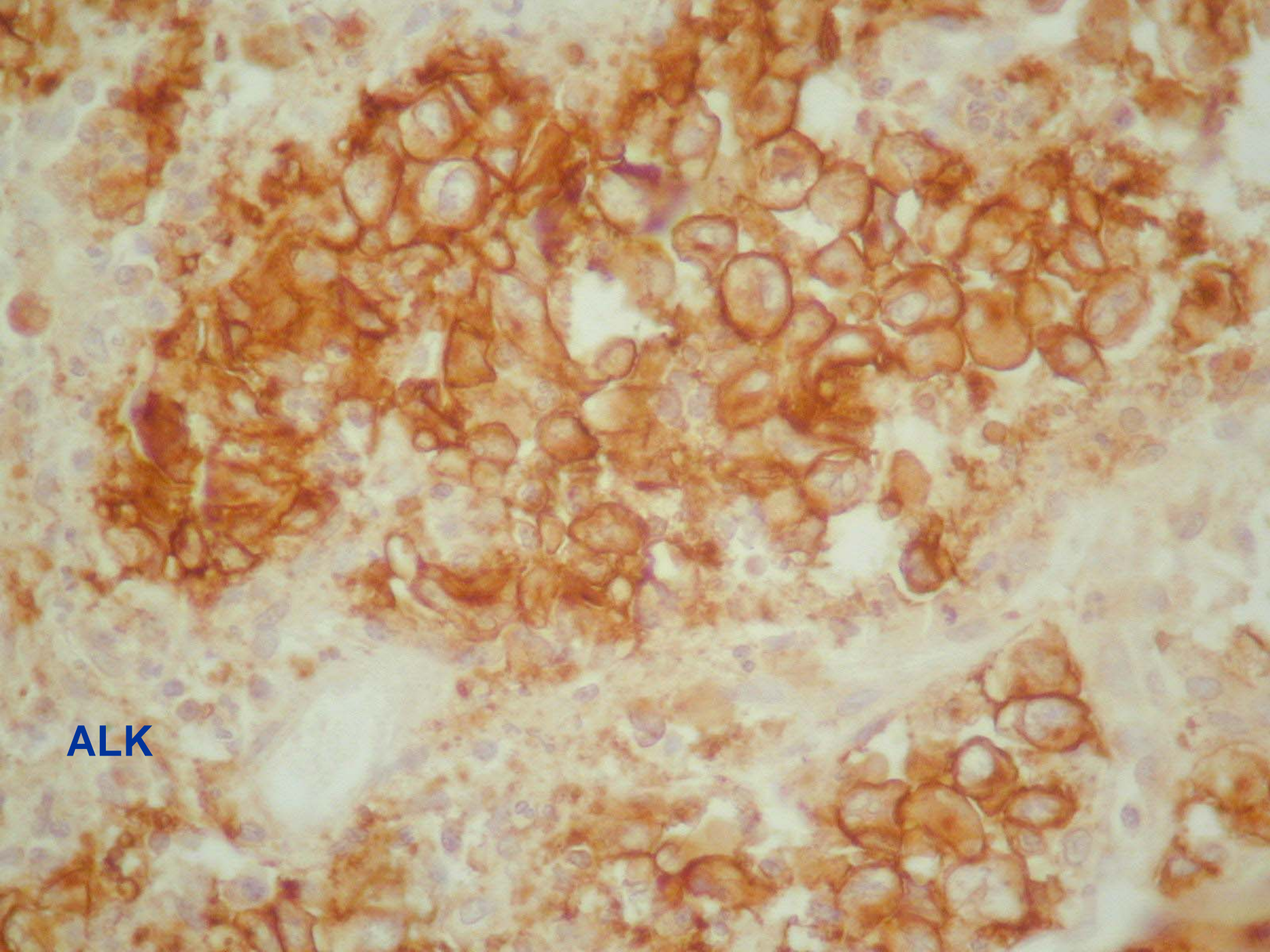




CD30



CD30



ALK

Diagnosis

- Anaplastic Large Cell Lymphoma (ALCL)
Primary Systemic, pediatric, T-cell Phenotype
CD30 +; ALK +; EMA +;

Anaplastic Large Cell Lymphoma

Discussion

Anaplastic Large Cell Lymphoma (T-Cell or Null-Cell)

Two clinical and biological distinctive subsets:

1. Primary Systemic form
2. Primary cutaneous form

Anaplastic Large Cell Lymphoma (ALCL), T or null cell type, **primary systemic form**

Definition (WHO 2001): Proliferation of large lymphoma cells of T cell type, with bizarr, anaplastic cytologic features

- # All cases are CD30= KI-1 positive

ALCL

- Majority are +ve for the (Anaplastic Large Cell Lymphoma Kinase (*ALK*) protein
- Majority are positive for ALK protein resulting for translocations involving ALK gene at 2p23

ALCL- epidemiology

- 2-7% of all NHL
- 10-30% of childhood lymphomas
- Frequent in the first three decades
- Male predominance
- ALK negative are prevalent in older individuals

ALCL- Sites

- Primary Systemic ALCA involves:
- Lymph nodes & extranodal sites:
 - Skin 21%
 - Bone 17%
 - Soft tissues 17%
 - Lung 11%
 - Liver 8%
 - CNS rare

ALCL: Histopath

- T zone involved & B zones spared
- Cohesive cell cords and sheets
- Large anaplastic cells
- Pleomorphic bizarr, wreathlike nuclei
- Nucleoli +++
- Atypical mitoses
- + LCA;CD30,EMA
- Negative for CD 15
- T-Cell markers (60%); B-cell markers (10%)
- Positive for protein *NPM**-*ALK*** detected by ALK-1 A-B

* Nucleophosmin ** Anaplastic lymphoma kinase

ALCL- variants

- Common Variant (60%)
- Lymphohistiocytic Variant (7%)
- Small Cell Variant (9%)
- Hodgkin like cell pattern (2%)
- Mixed pattern (15%)
- Monomorphic variant
- Hypocellular variant
- Giant cell variant
- Sarcomatoid variant
- Unclassified
- ALK-negative (phenotypic variant): Large and more pleomorphic cells and more aggressive clinical course

Translocations and fusion proteins involving ALK at 2p23

Translocation	Fusion Protein	Frequency
t(2;5)	NPM-ALK	75 %
	Tropomyosin 3	
t(1;2)	TPM3-ALK	15%
	Trk Fusion Gene	
t(2;3)	TFG-ALK	~2%
	ATIC (Pur H gene)	
Inv2	ATIC-ALK	~2%
	Clathrin heavy chain	
t(2;17)	CLTC-ALK	~1%
	Moesin	
t(2;X)	MSN-ALK	~1%
	Non Muscular myosin heavy chain	
t(2;22)	MYH9-ALK	~1%
	Tropomyosin 4	
t(2;19)	TPM4-ALK	~1%
	ALO 17	
t(2;17)	ALO17-ALK	~1%

ALK+

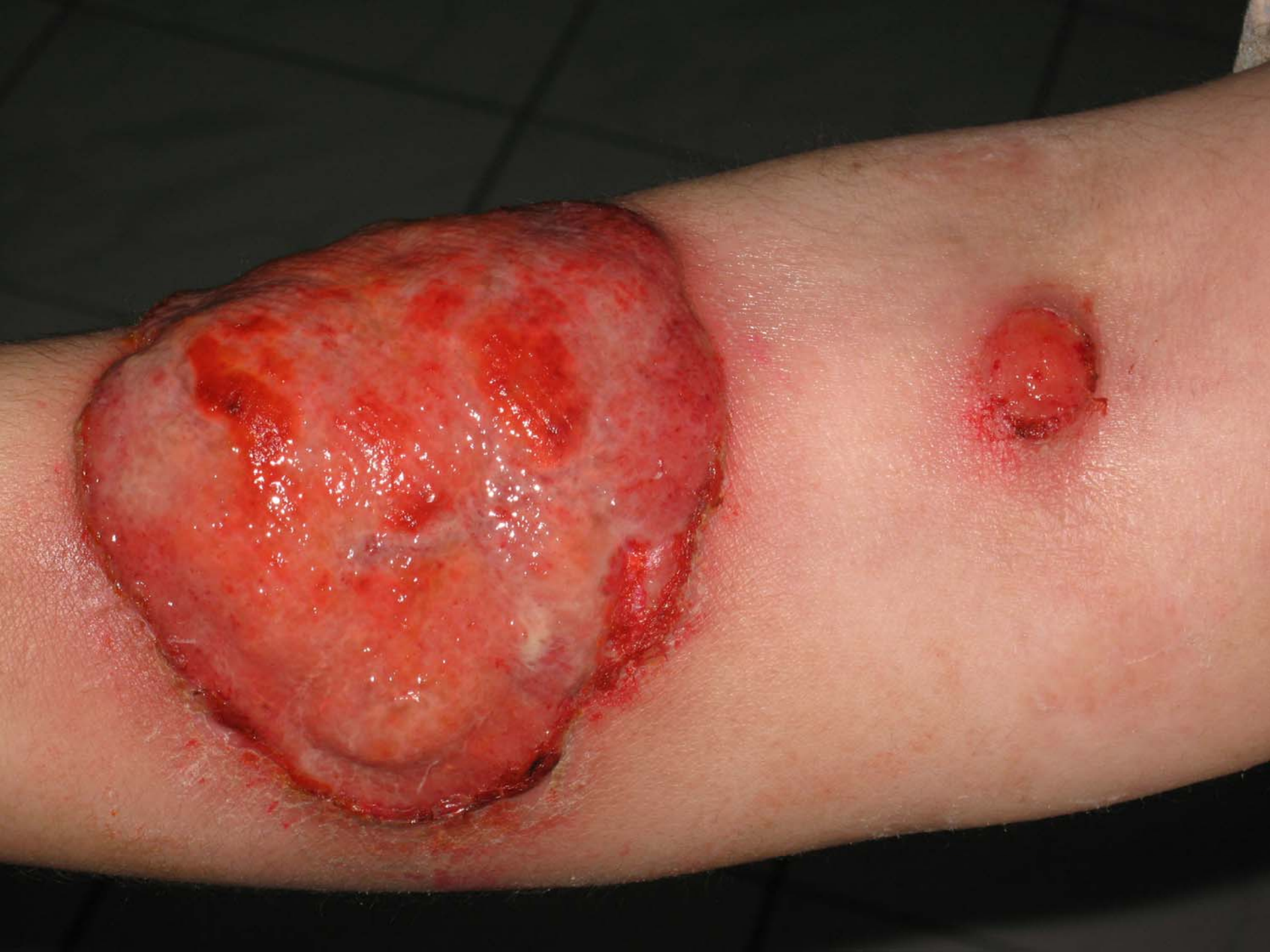ALCL- Differ. Diagnosis

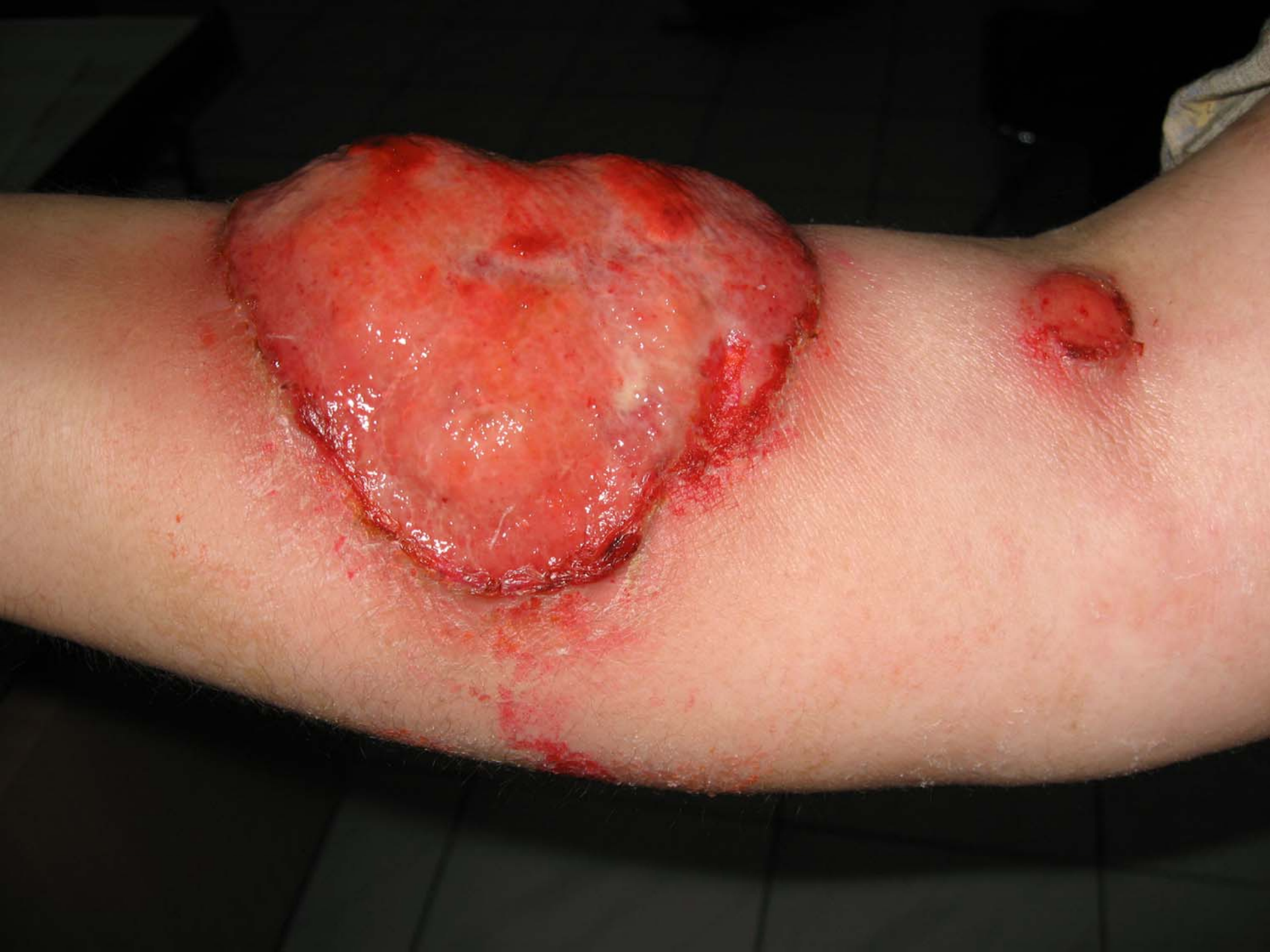- Hodgkin's Lymphoma (B-cell neoplasm with CD15 positive)
- Diffuse Large B-Cell Lymphoma (B-cell markers) → some DLNHL show CD30 + ...
- Histiocytic sarcoma & malignant histiocytosis
- Metastatic Carcinoma - Melanoma

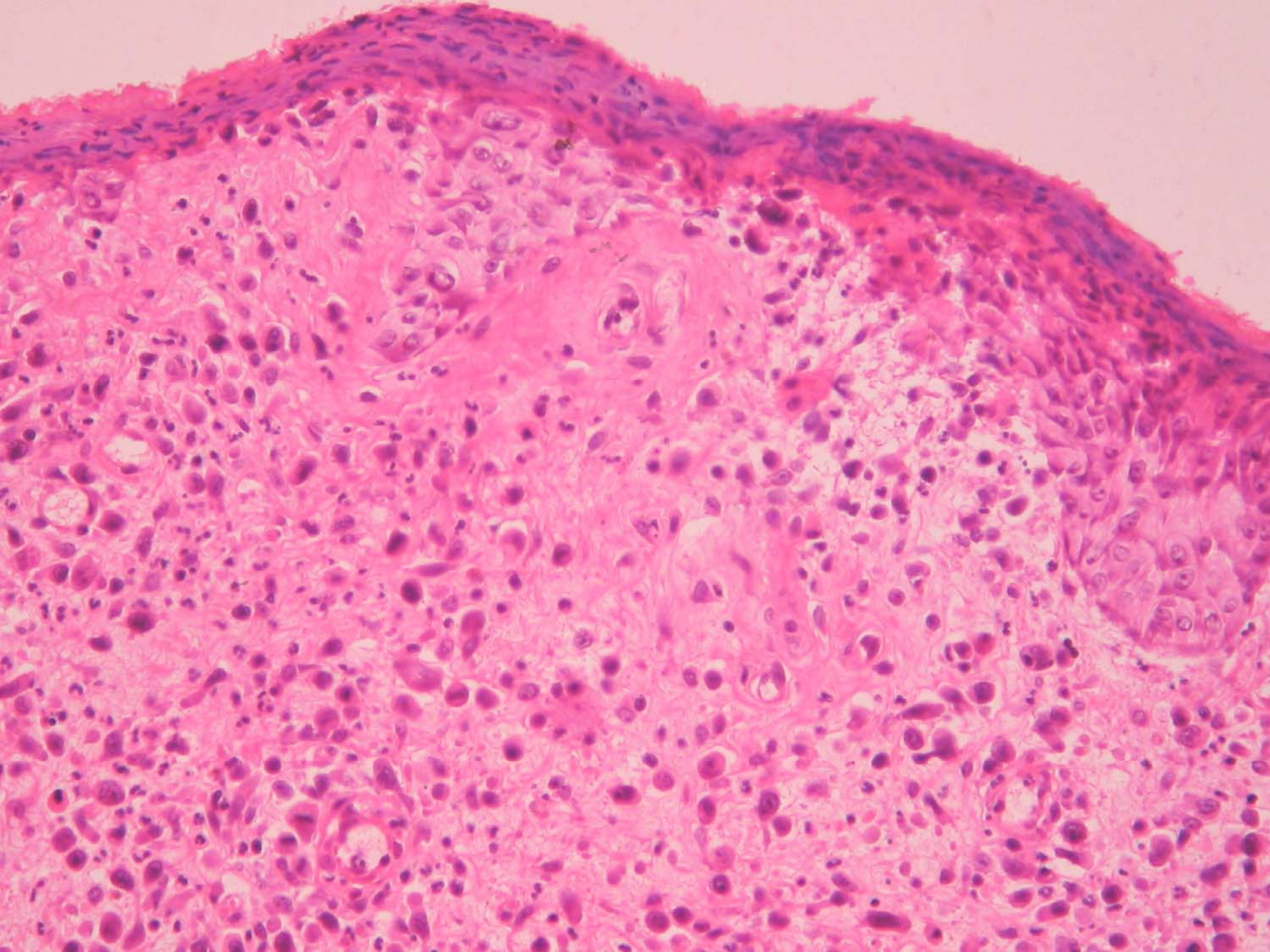


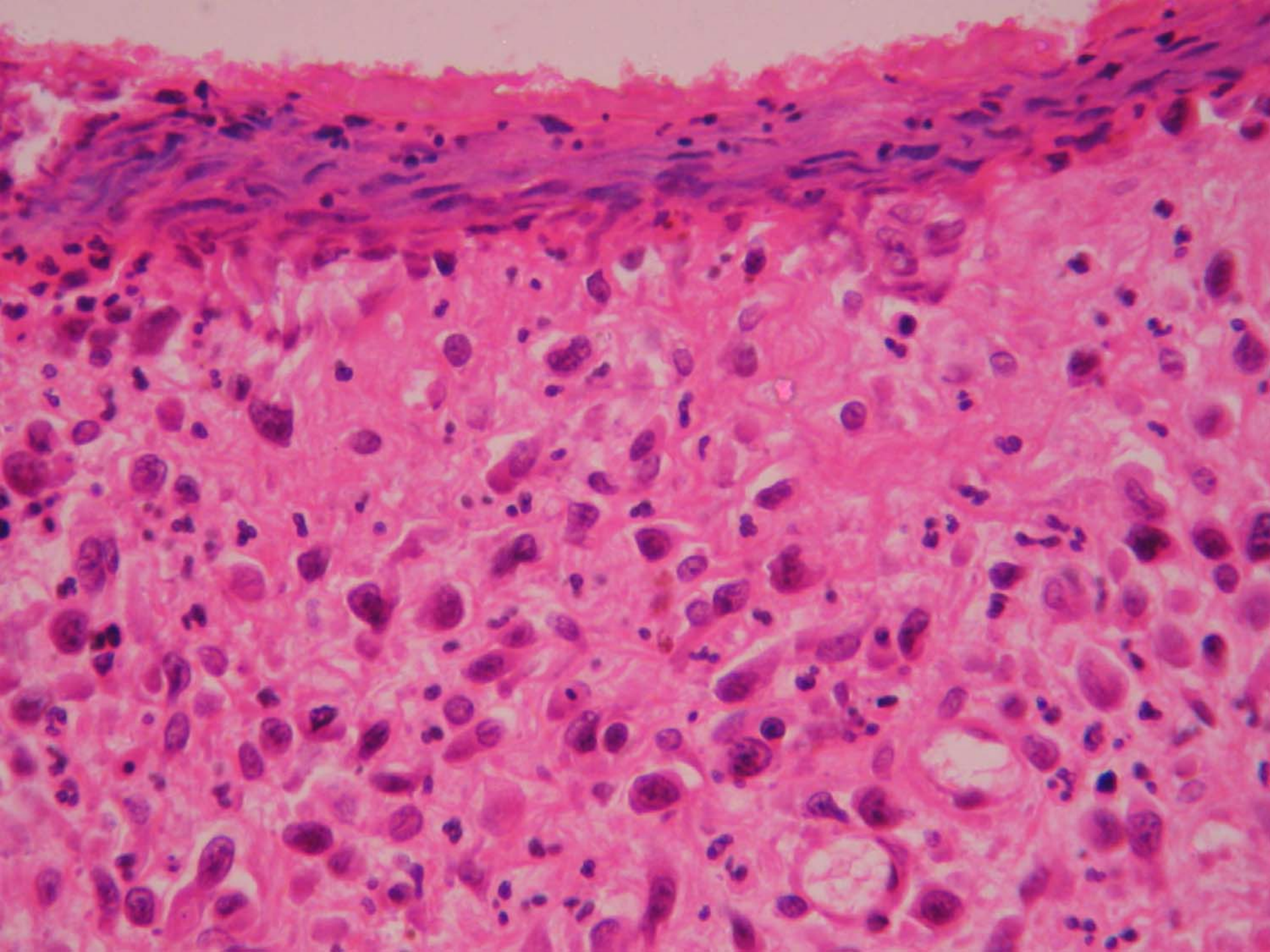
Case 4/ 047251

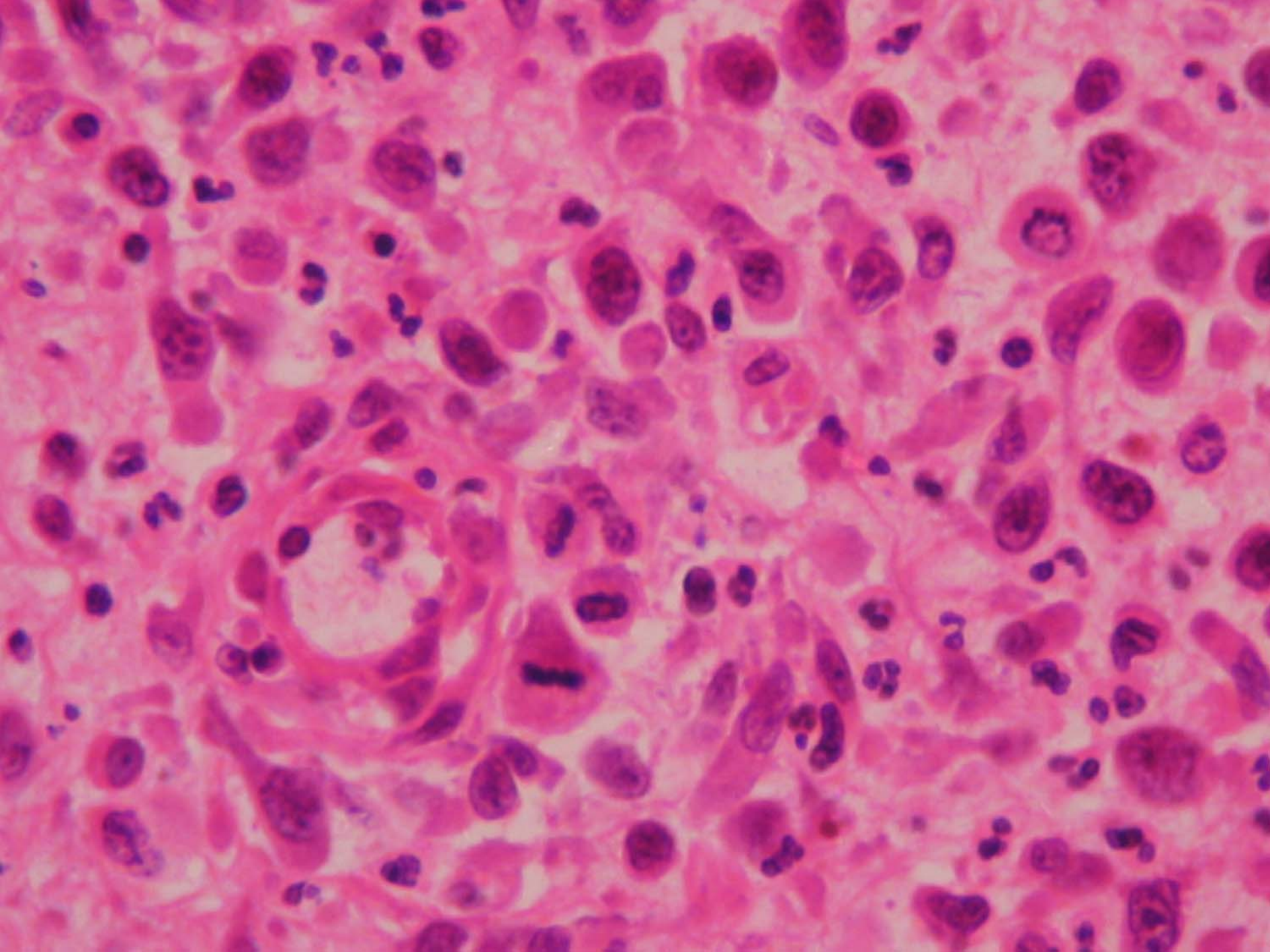
- 38 years female
- Incisional biopsy from a tumor mass of the forearm since 8 months
- Clinical Diagnosis:
 - Pyodermite vegetante ?
 - -Pyoderma gangrenosum?
 - Lymphoma ?

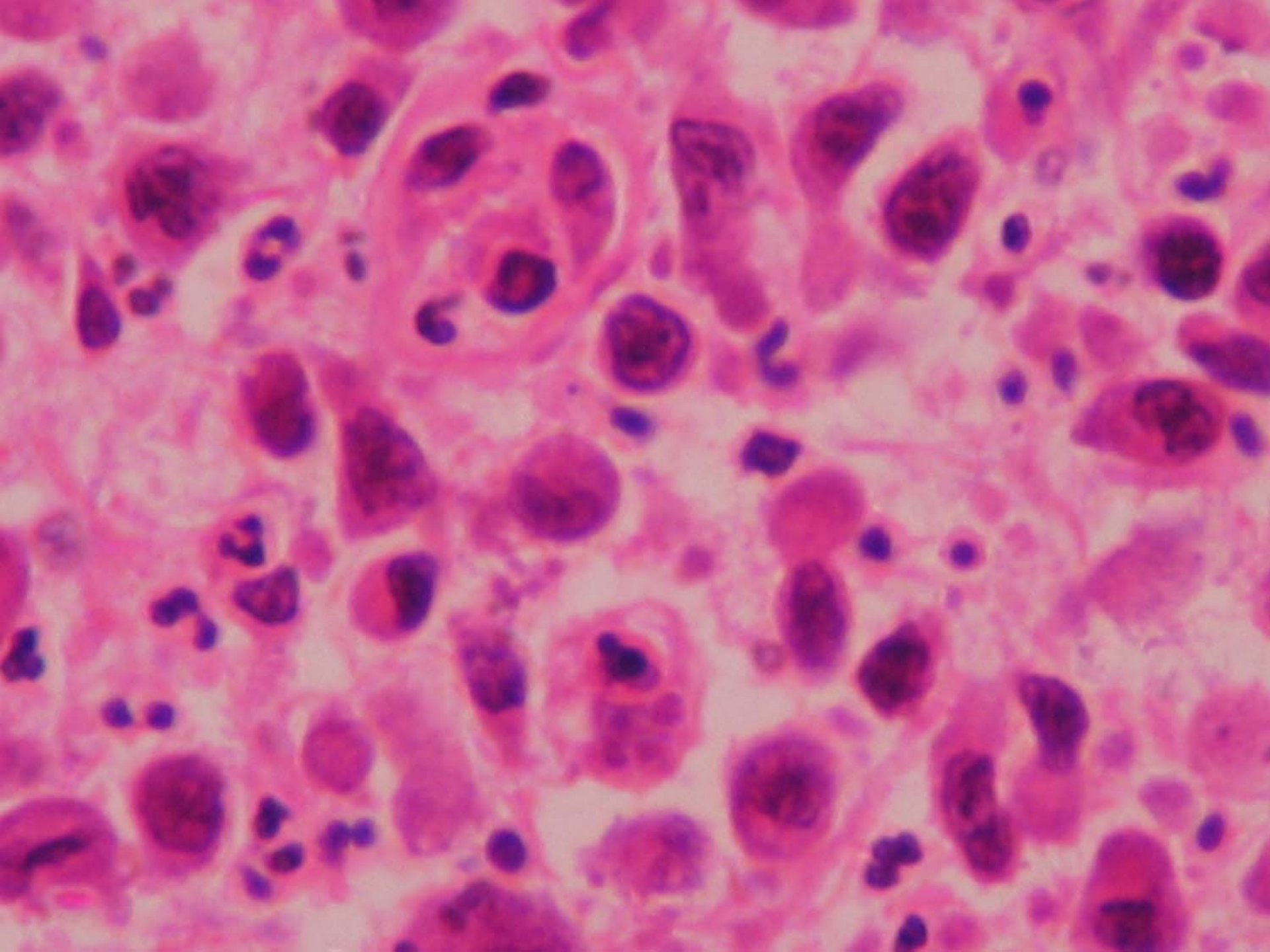


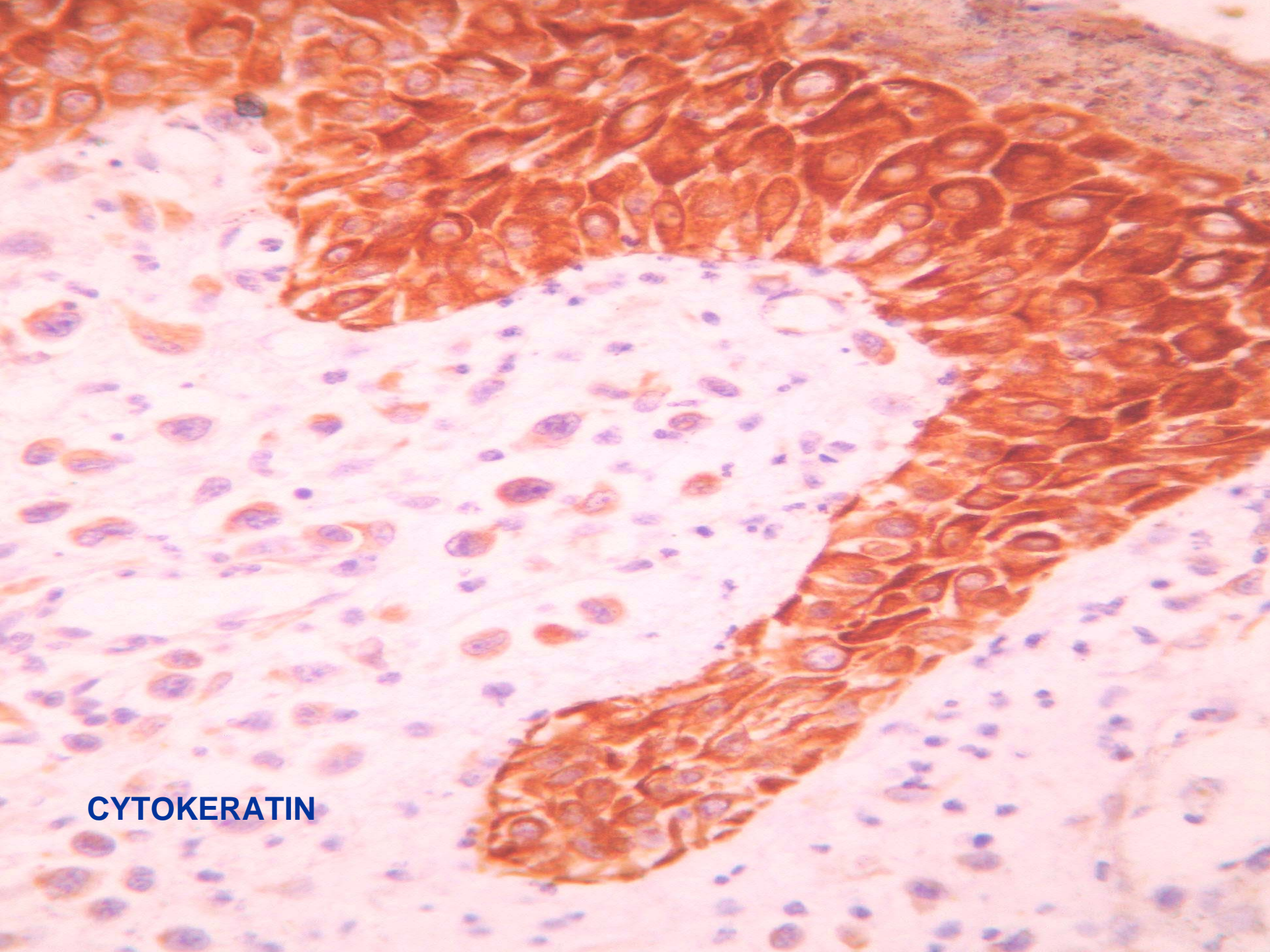




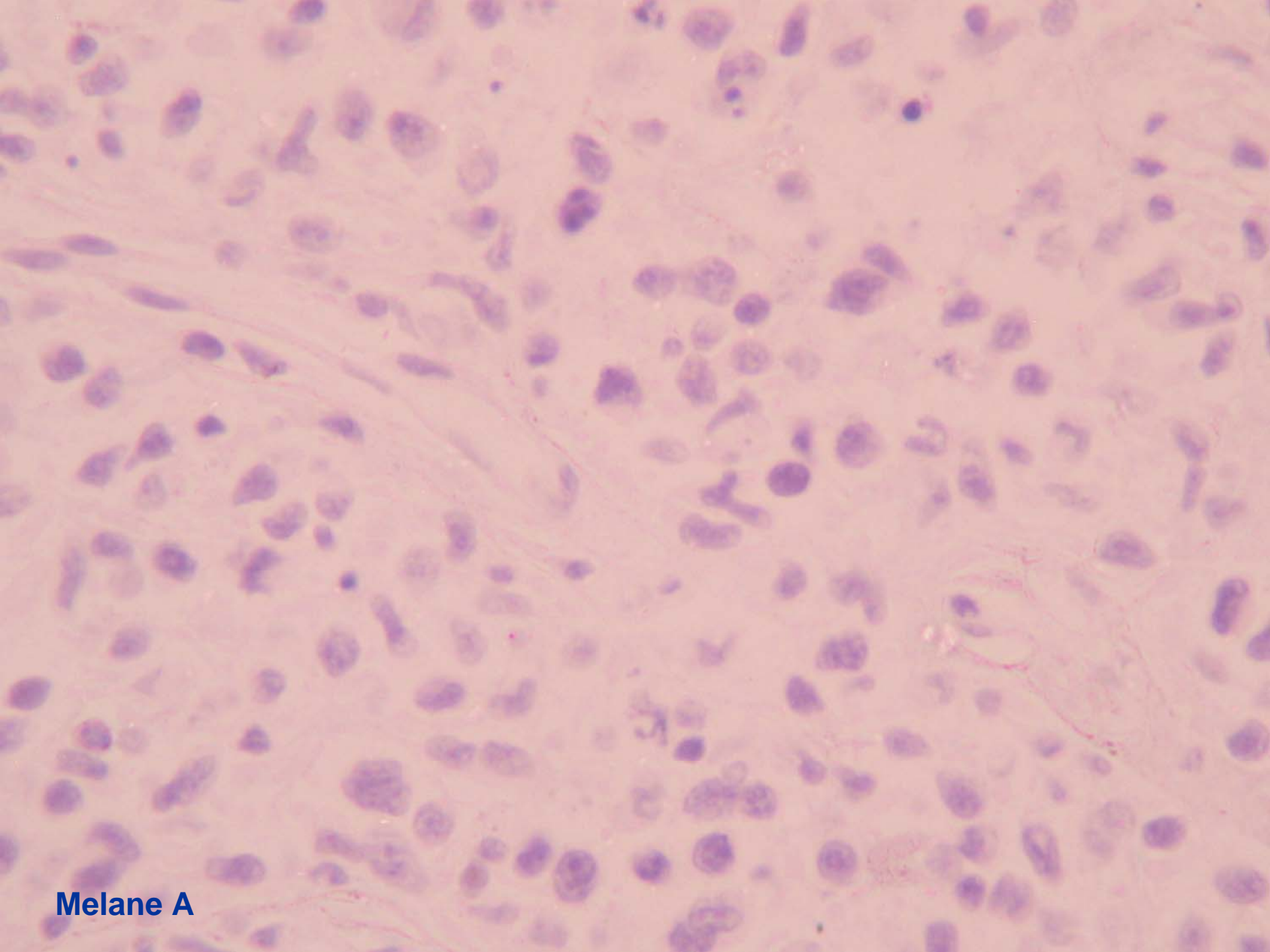




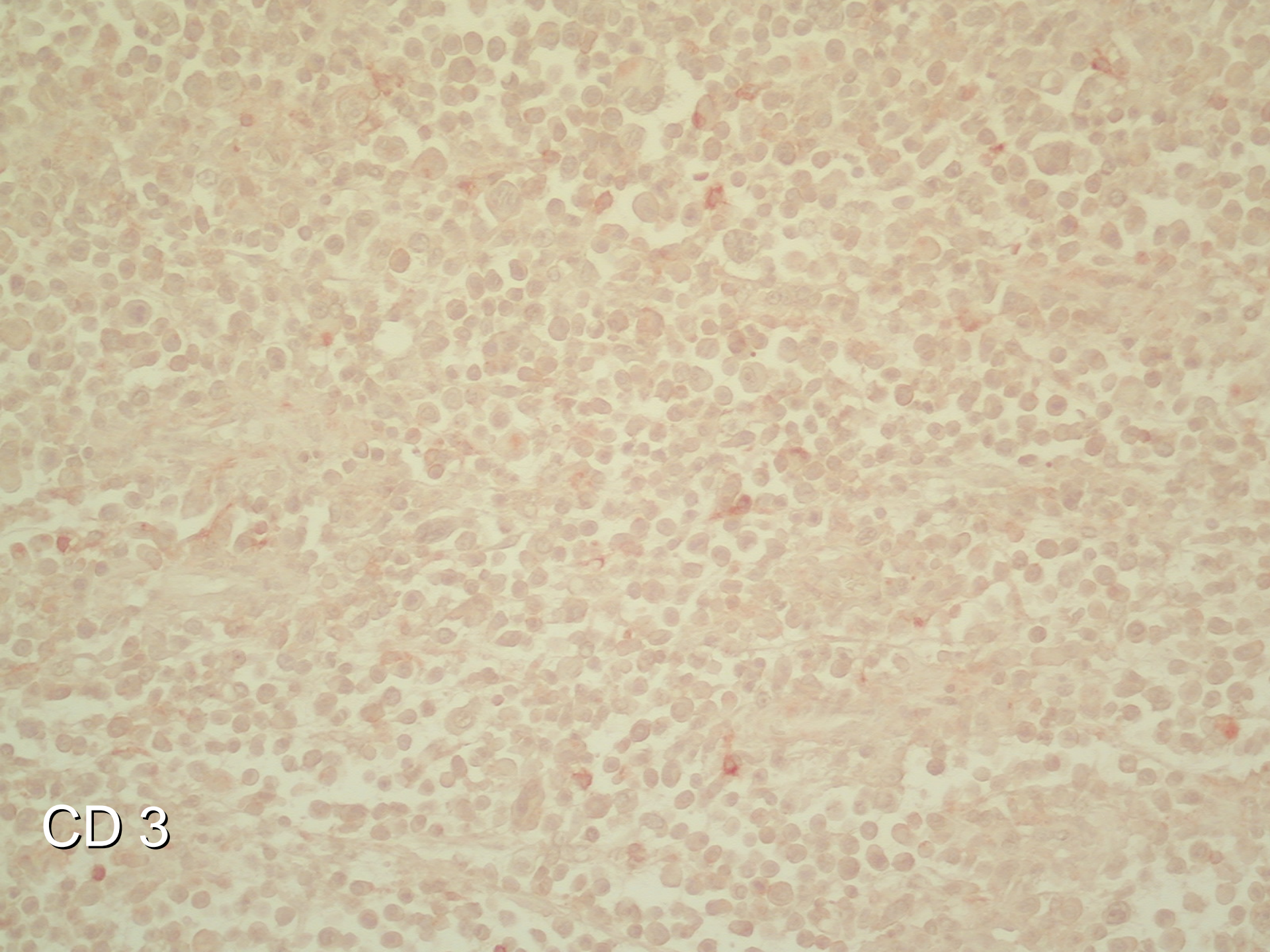




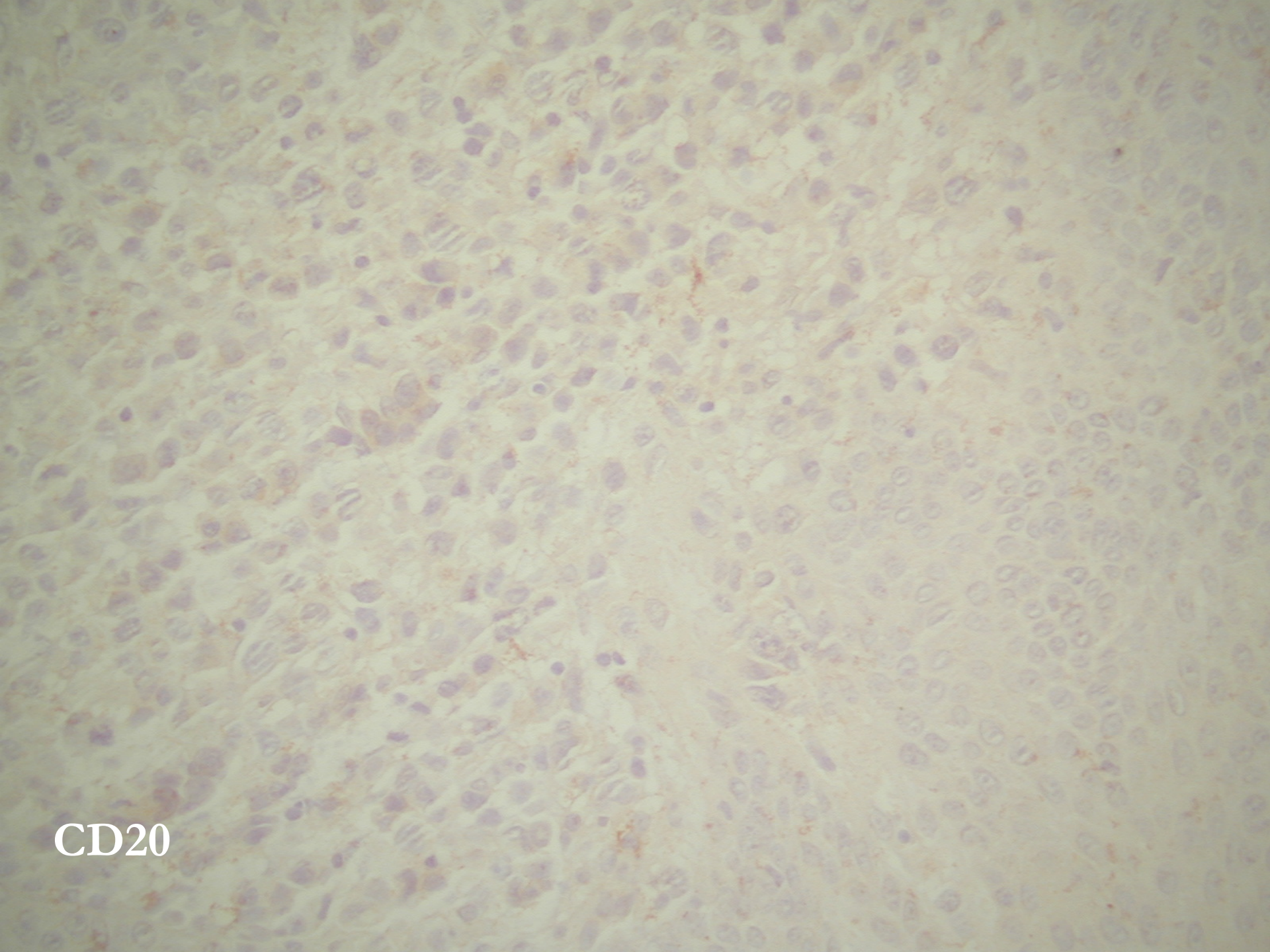
CYTOKERATIN



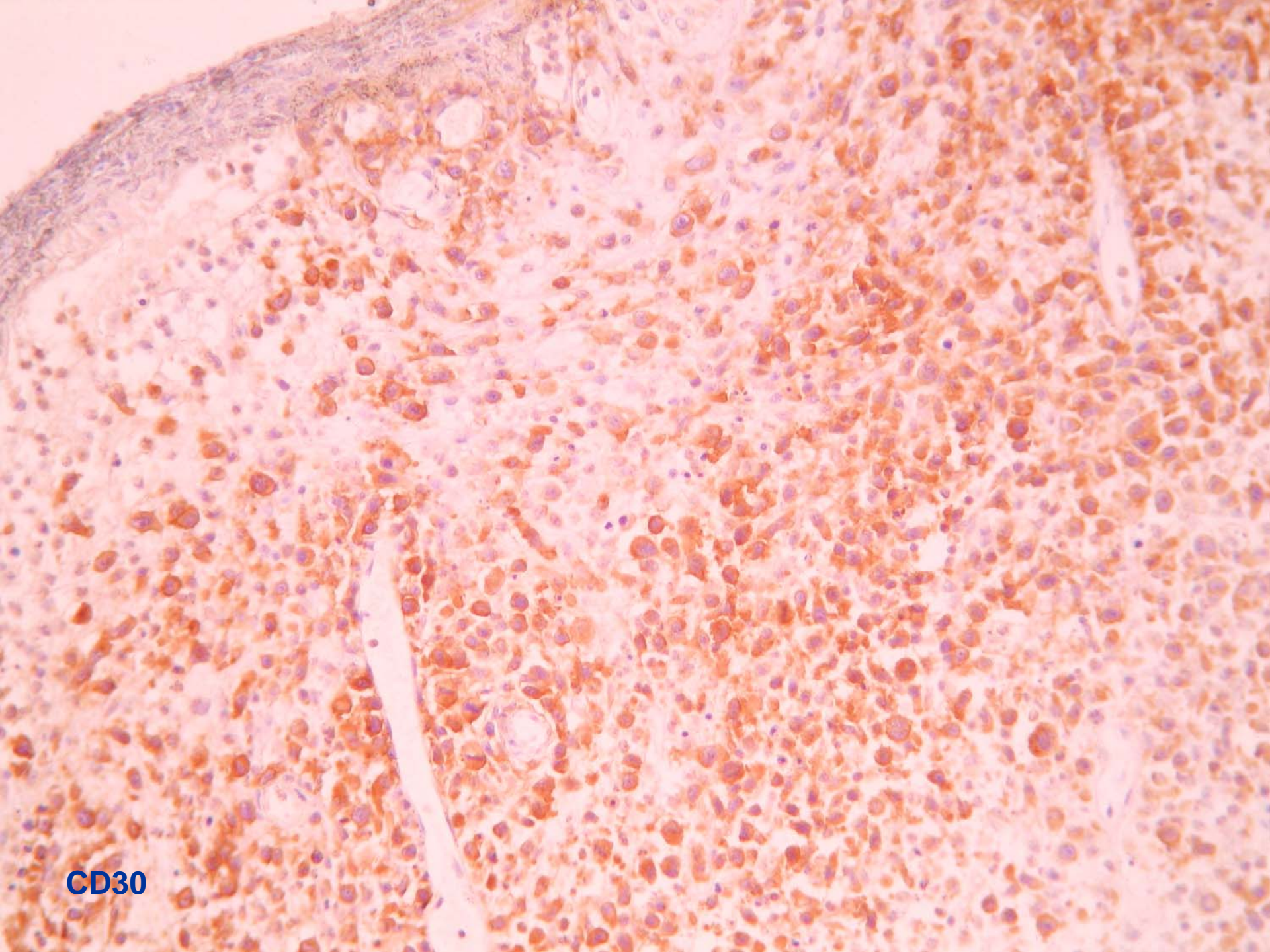
Melane A



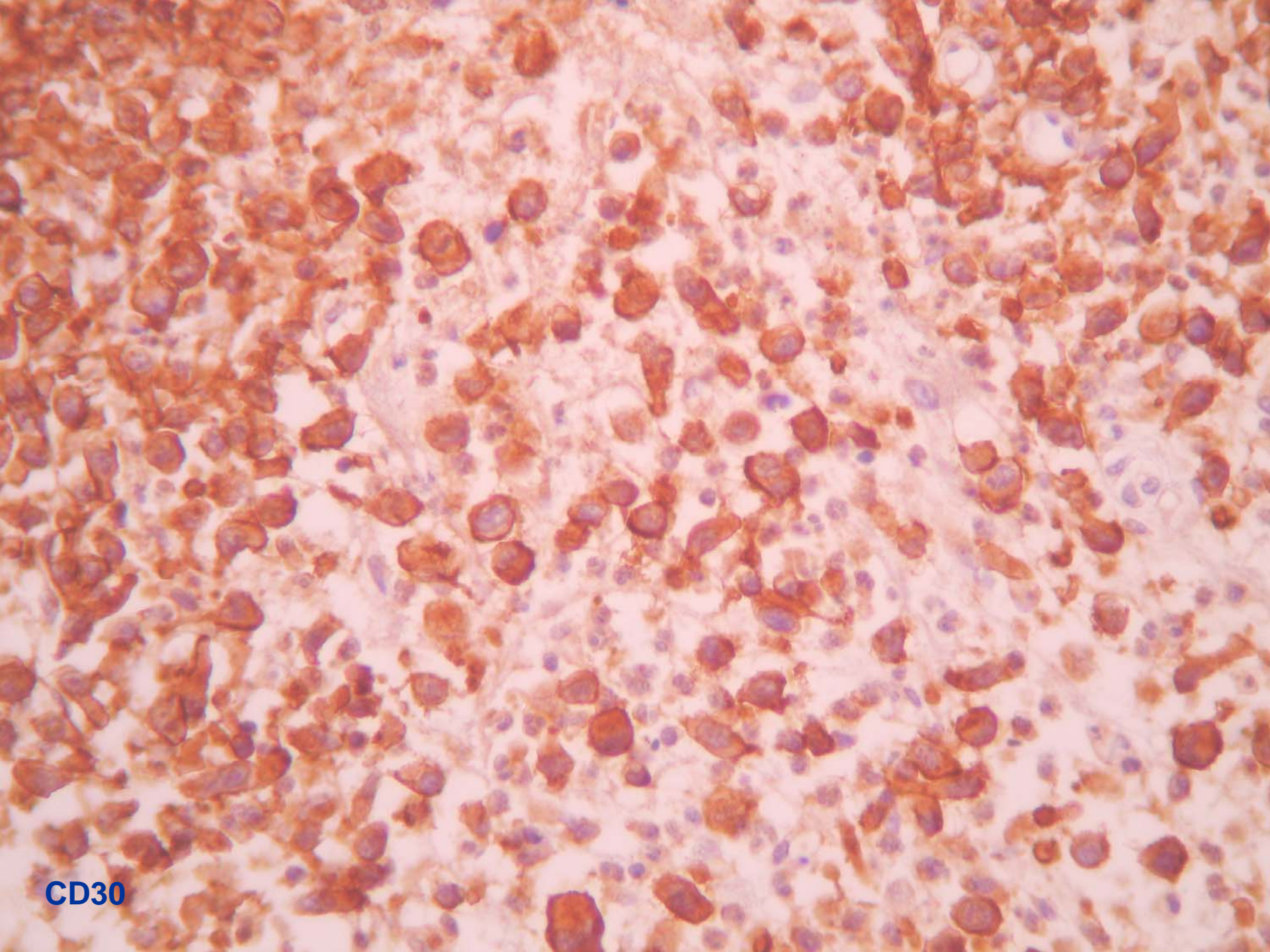
CD 3



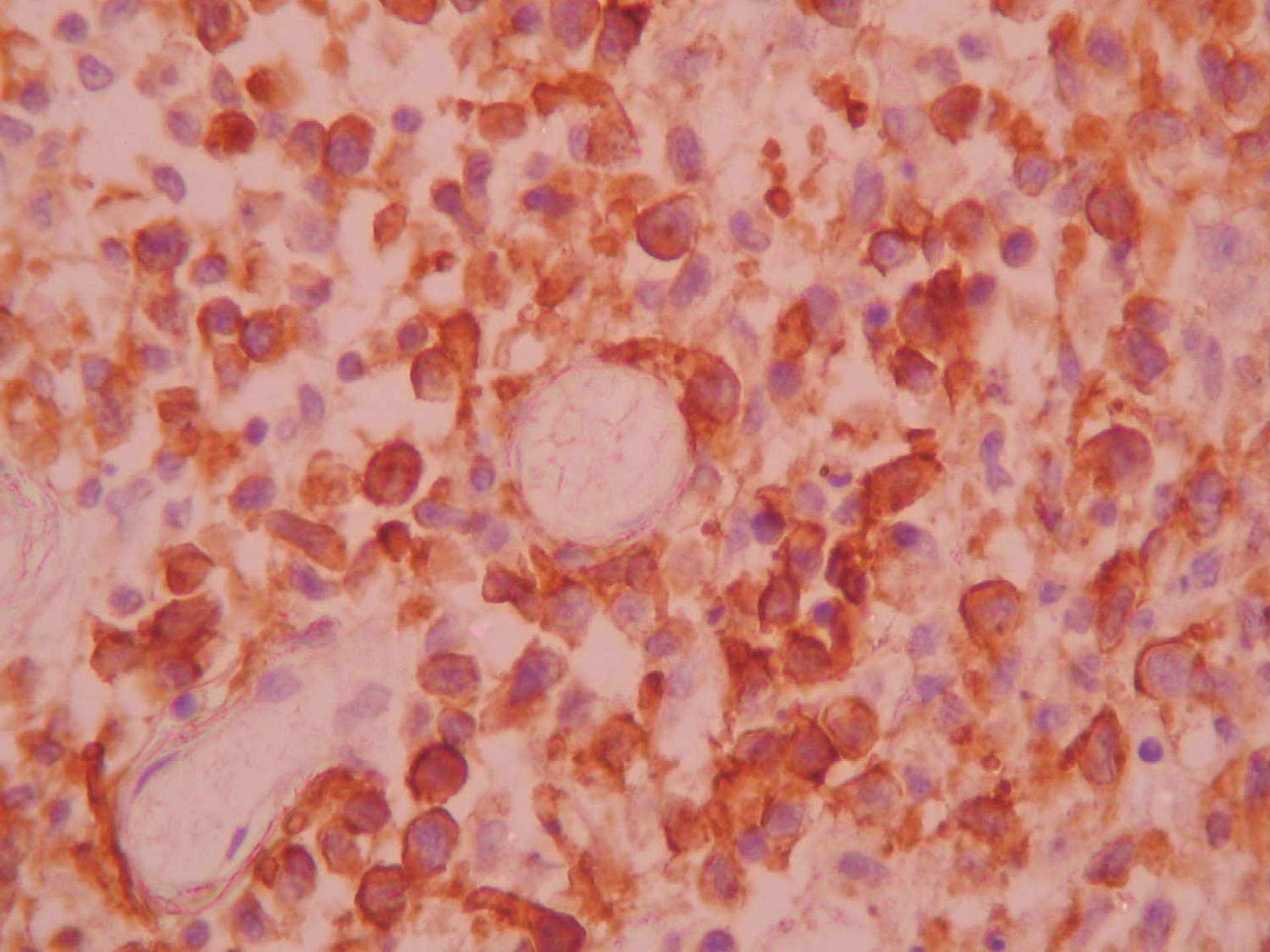
CD20



CD30



CD30



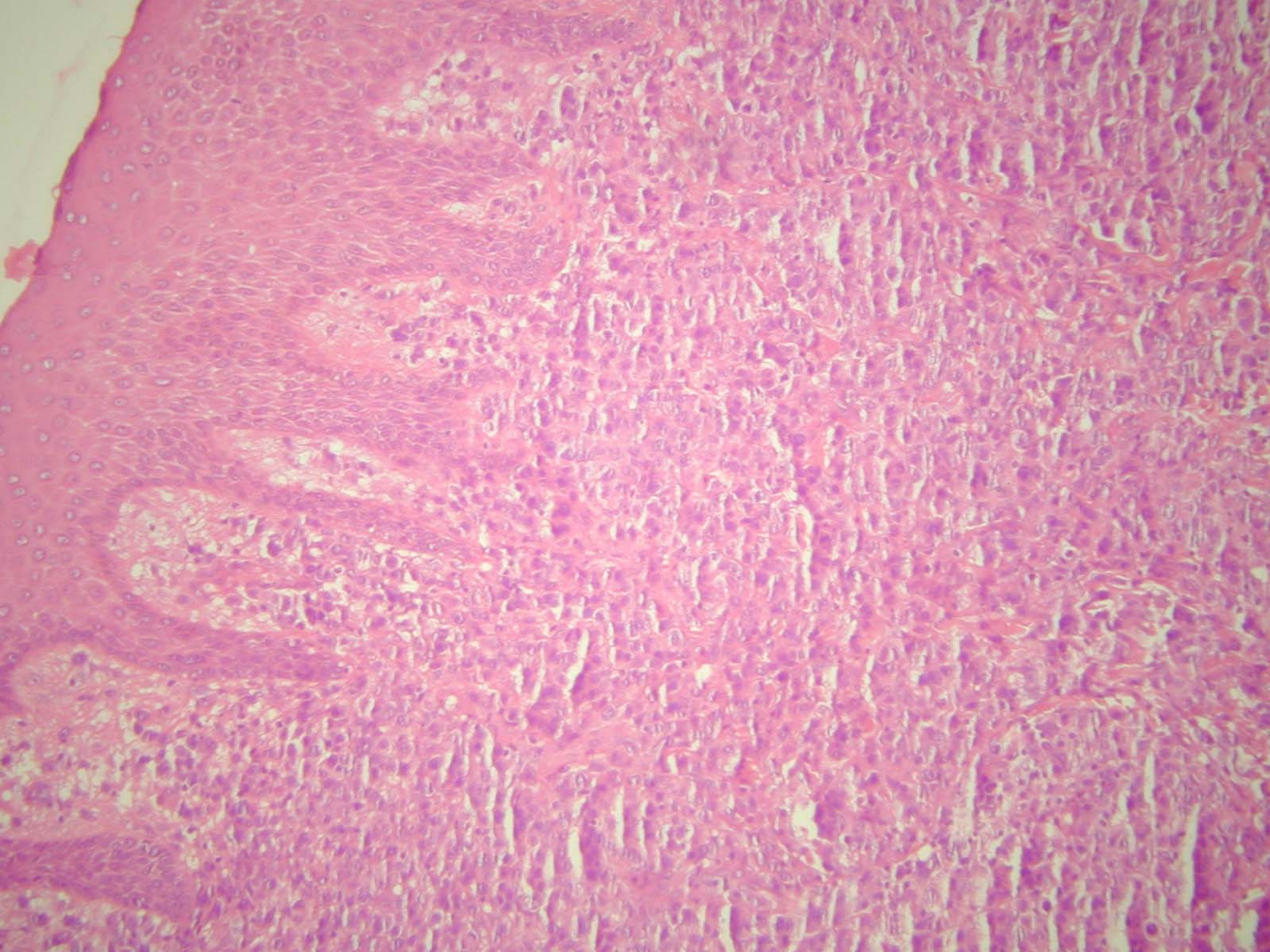
ALK

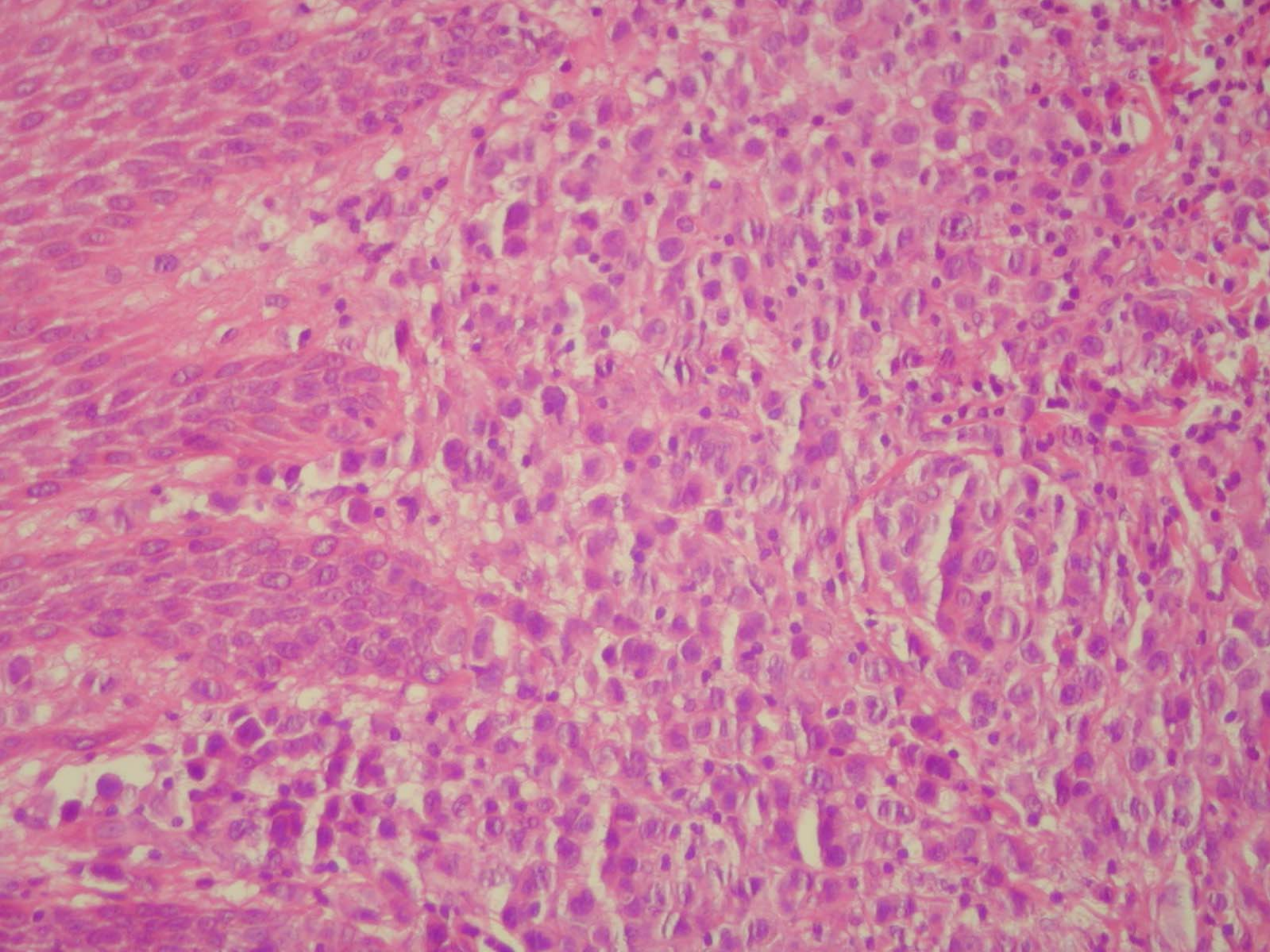
diagnosis

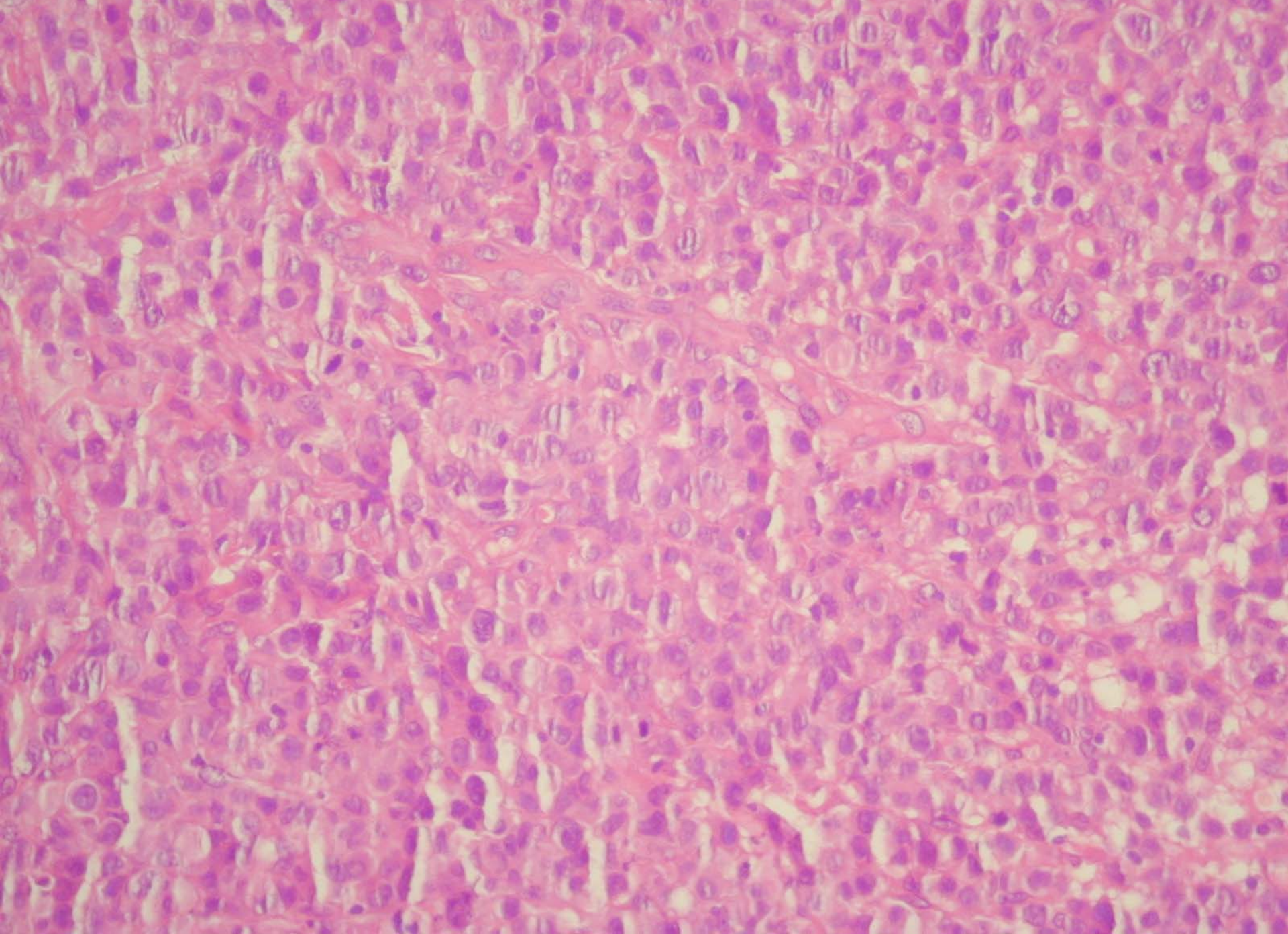
- Primary Cutaneous Anaplastic Large Cell Lymphoma, null-cell type
CD30 +; ALK – and CD3 -

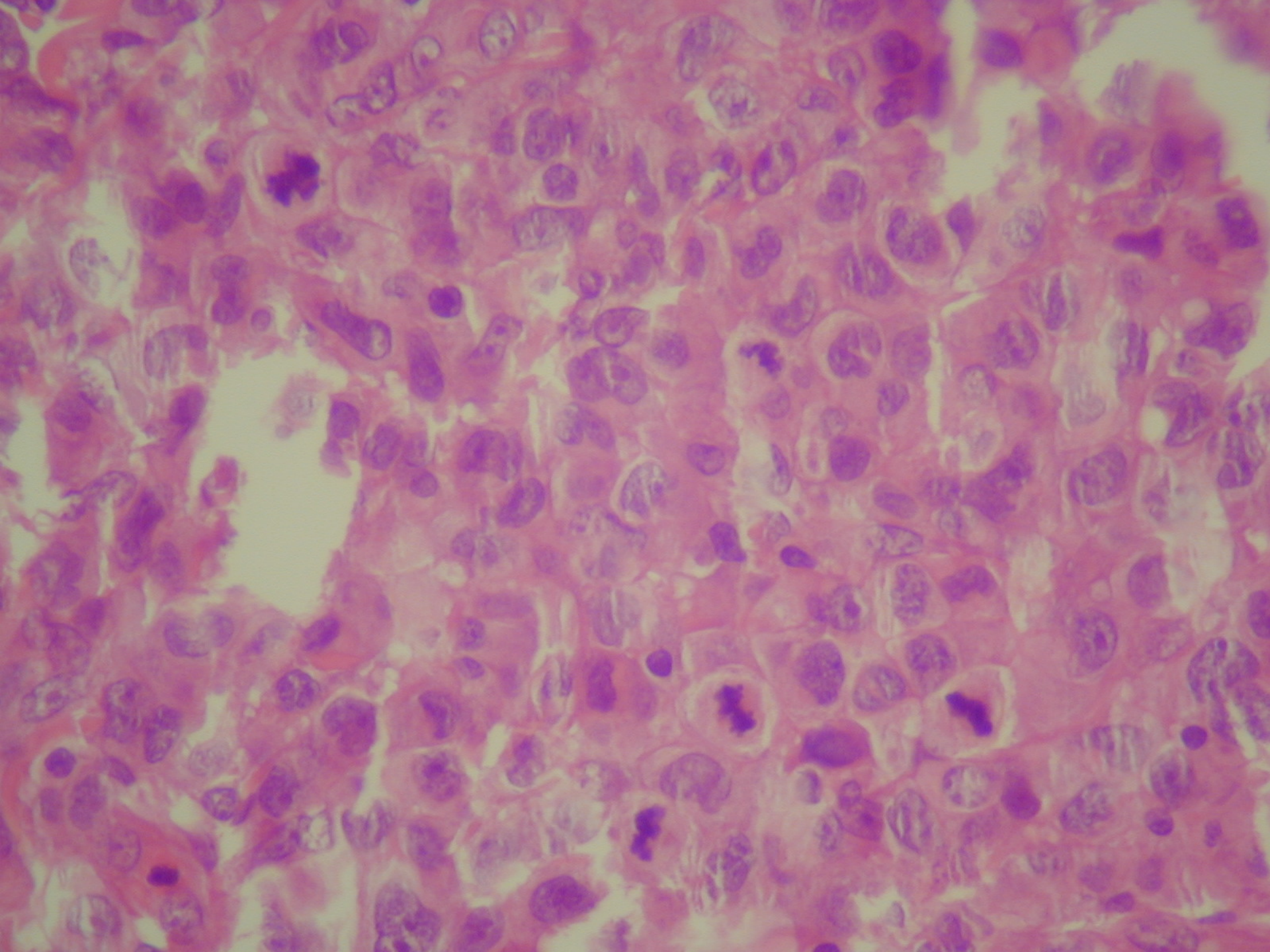
Case 5 Abousamir

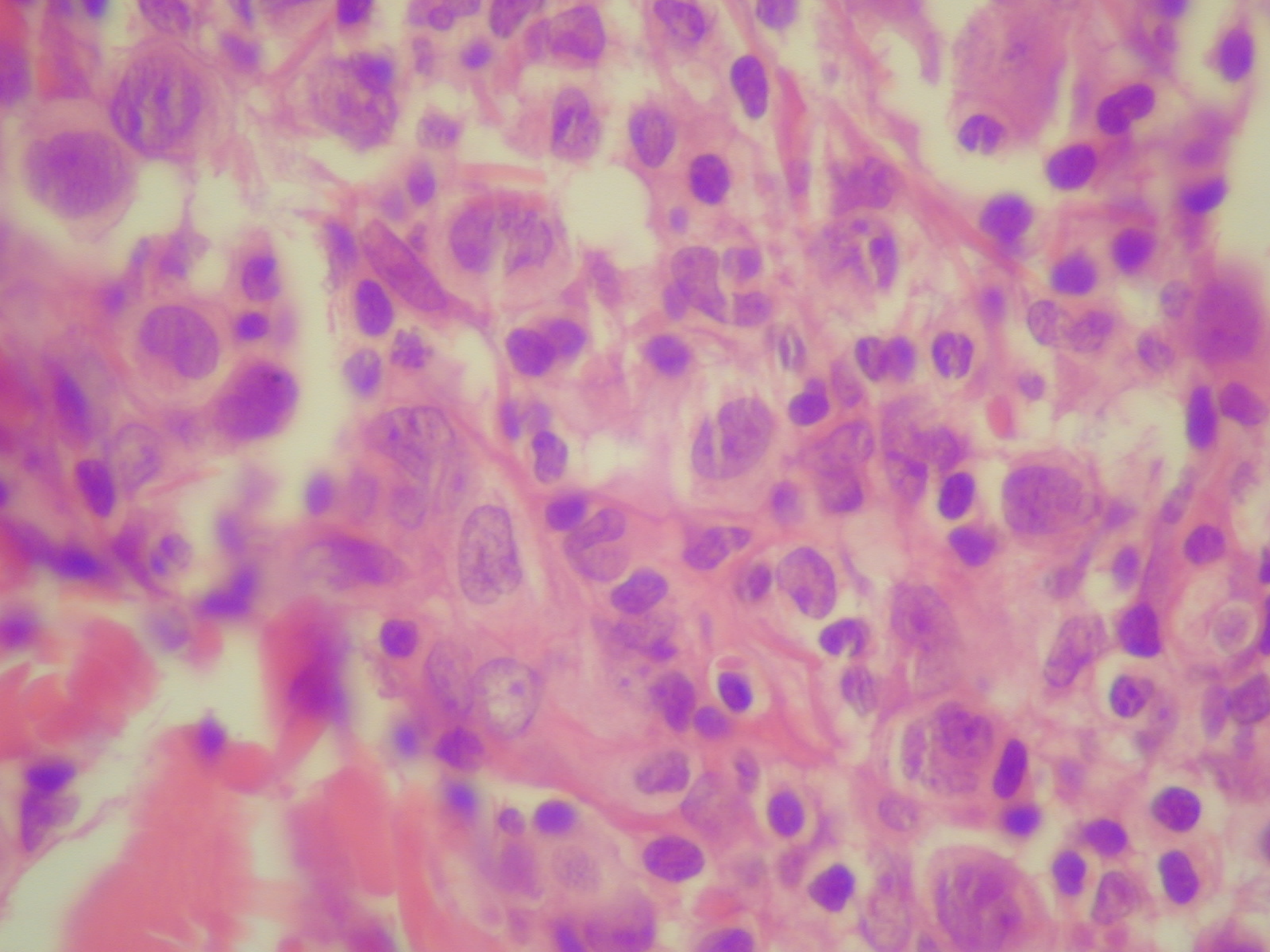
- 82 years old man
- Recurrent lesion of the skin (thigh)
- After excision and radiotherapy since 8 years
- Received: A wedge biopsy 1,5cm
- Routine stain and Immunohistochemistry

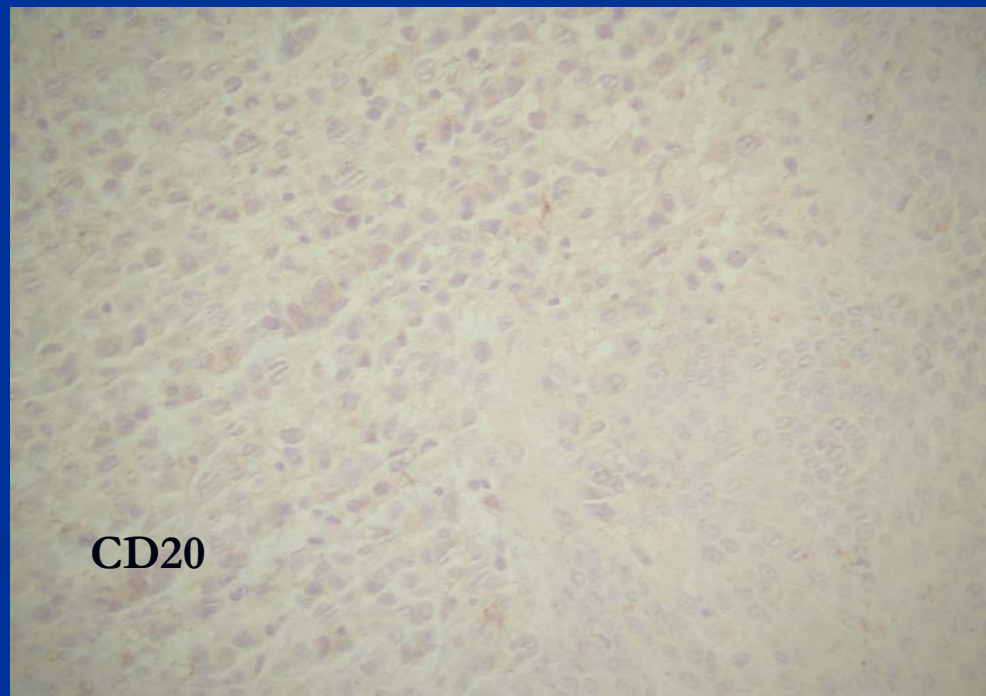
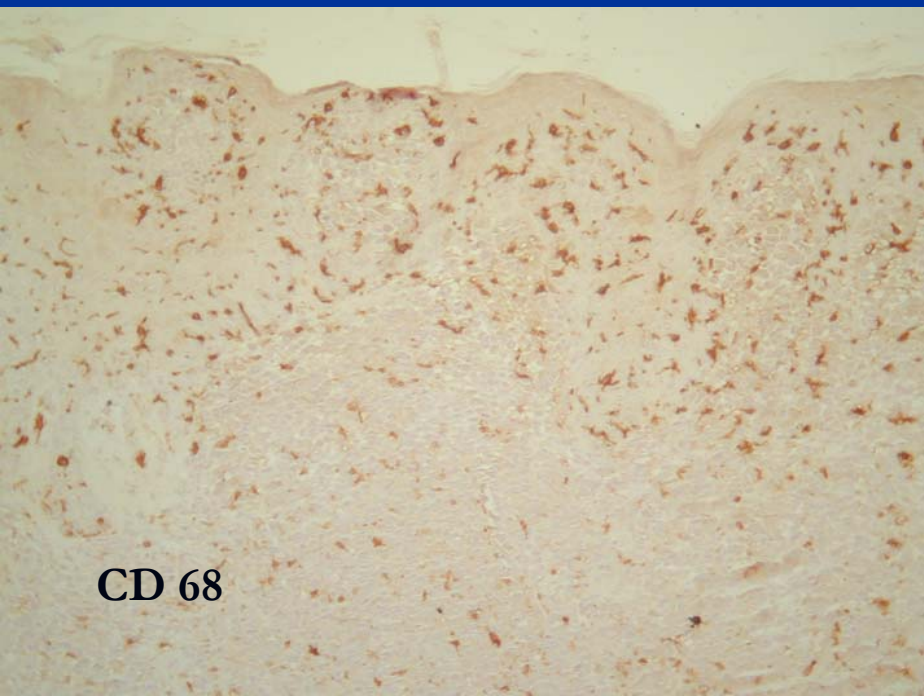
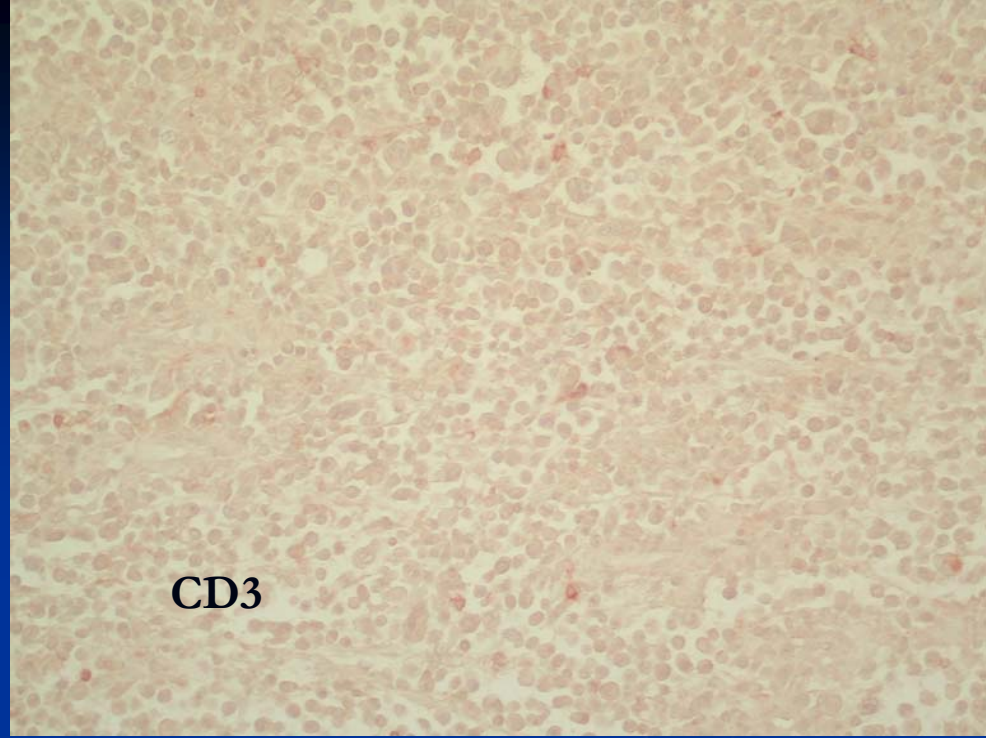
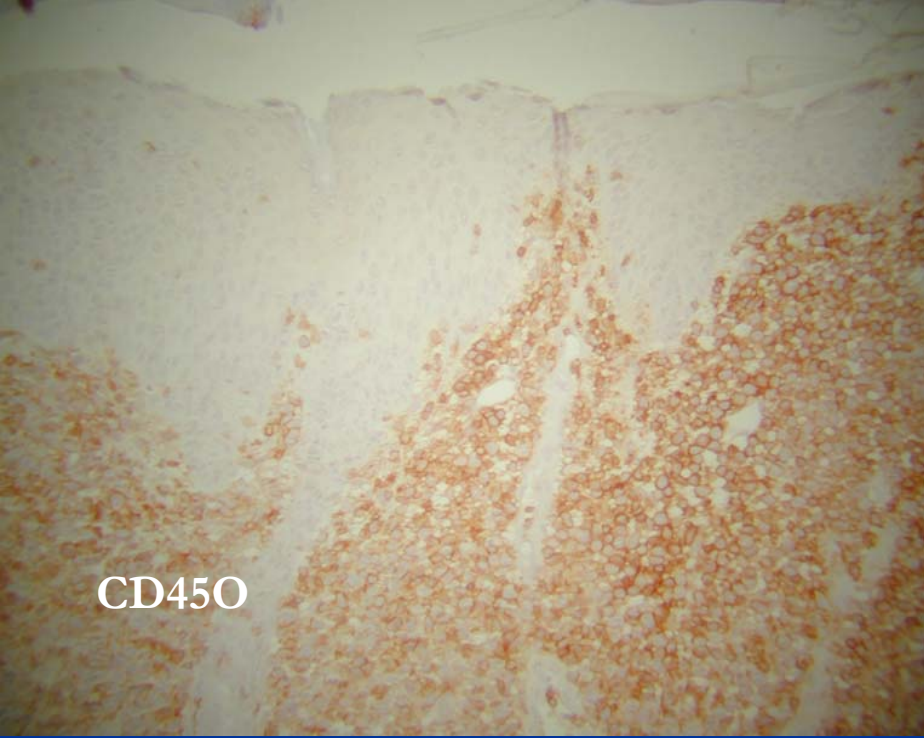


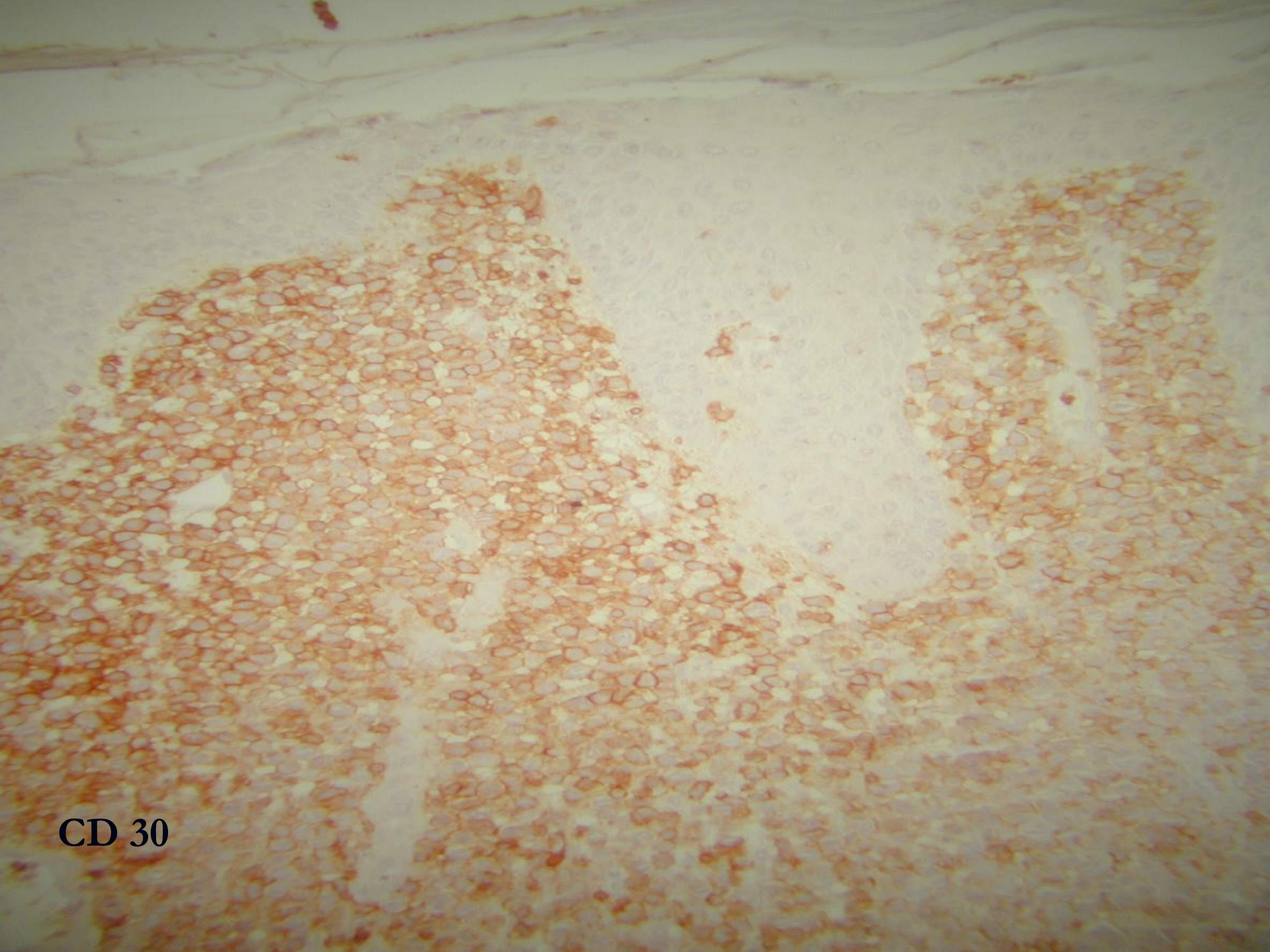












CD 30

Diagnosis

Primary Cutaneous Anaplastic Large Cell
Lymphoma, T-Cell type

Primary Cutaneous Anaplastic Large Cell Lymphoma

- 25% of the T-cell lymphomas, primary in the skin
- Adults +++
- Regresses spontaneously or Relapsing course
= (Regressing Atypical Histiocytosis)

Primary Cutaneous ALCL

Histopath

- Ulcerated skin
 - 10-20% are B-Cells
 - 20-30% : (B+T) or (Non B Non T) or Histiocytic
 - All Cases are CD 30 +
 - 50% EMA +
 - 60% of neoplastic cells are T
 - Involvement of dermis and hypodermis
 - Cells are anaplastic with amphophilic cytoplasm
 - Irregular folded nuclei; vesicular chromatin
- Embryo-like appearance binucleation and multinucleation

ALCL cutaneous lymphoma

Microscopy:

- Prominent nucleoli
- Paranuclear Golgi zones are present
- Squamoid cell appearance
- Mitoses +++
- Necrosis +

